

# Influence of Respiratory Pattern On Craniofacial Growth

JAMES A. MCNAMARA, JR.

*Dr. McNamara is an Associate Professor of Anatomy and Research Scientist, Center for Human Growth and Development at the University of Michigan, and in the private practice of orthodontics in Ann Arbor. He is a dental graduate of the University of California at San Francisco and holds a Certificate in Orthodontics from the same institution and a Ph.D. degree in Anatomy from the University of Michigan.*

## Address:

Dr. James A. McNamara  
Center for Human Growth and  
Development  
1111 East Catherine  
Ann Arbor, MI 48109

*Presented at the 1981 meeting of the Midwest component of the Edward H. Angle Society of Orthodontists.*

*The author wishes to thank Dr. Thomas Laboe and Dr. Robert Bushey for providing the records of two of the patients presented in the case reports and Ms. Kathleen O'Connor and Ms. Julie Hammond Weir for help with the literature search. The author also acknowledges the assistance of Ms. Katherine Ribbens and Ms. Andrea Appel in the preparation of the manuscript. Illustrations by Eugene G. Leppanen. This research was supported in part by USPHS Grant DE-03610 from the National Institute for Dental Research. The tonsil and adenoid study at the Children's Hospital of Pittsburgh is supported by USPHS Grant HD 07403 from the National Institute of Child Health and Human Development.*

*Mouth breathing is an inevitable result of obstruction of the nasal airway. Associated changes in mandibular posture and the function of related muscles have long been postulated to cause undesirable changes in facial growth. Evidence for such a cause-effect relationship is reviewed and illustrated with clinical records.*

---

Nasorespiratory function and its relation to craniofacial growth is of great interest today, not only as an example of the basic biological relationship of form and function, but also because it is of great practical concern to pediatricians, otorhinolaryngologists, allergists, speech physiologists, orthodontists, and other members of the health care community as well. Discussions on this topic have appeared in the literature for over a century. Recent renewed interest is based on the accumulating findings in investigations of the relationship between breathing patterns, craniofacial growth and dentofacial orthopedic treatment.

## CLINICAL STUDIES OF RESPIRATORY OBSTRUCTION

The classic clinical example of the possible relationship between airway obstruction and aberrant craniofacial growth is the type of patient described as having "adenoid facies" (e.g. Meyer, 1872; Angle, '07; Johnson, '43; Ricketts, '68; Moore, '72; Linder-Aronson, '79). These patients usually present a

mouth-open posture, a small nose with button-like tip, nostrils that are small and poorly developed, a short upper lip, prominent upper incisors, a pouting lower lip, and a vacant facial expression. Mouth-breathing individuals have been classically described as possessing a narrow, V-shaped maxillary arch, a high palatal vault, proclined upper incisors, and a Class II occlusal relationship.

The emphasis on the "adenoid facies" patient in the literature has been unfortunate in one sense, because it implies that all patients having these facial characteristics are mouth breathers and that all mouth breathers have these facial characteristics. This is not always the case (Thurow, '75). Studies of clinical populations have indicated that obstructed respiratory function can be found in patients with a variety of facial types. Howard ('32) reviewed 500 patients with histories of tonsil problems. Of the 159 patients he classified as being mouth breathers, 59% presented with normal occlusions, 14% with Class II malocclusions and 27% with either Class I or Class III malocclusions.

Leech ('58) studied 500 patients who were being treated for upper respiratory problems. Nineteen percent were classified as mouth breathers, two-thirds of whom had obstructive adenoids and one-third of whom had such conditions as allergy, infective rhinitis and septal defects. More than 60% of the mouth-breathing patients were Class I, 25% were Class II, and 10% were Class III.

Huber and Reynolds ('46) studied a random sample of 500 male college students, only 27 of whom were characterized as being mouth breathers. Sixty-two percent of the mouth breathers had Class I molar relationships, 30% had Class II molar relationships,

and 8% had Class III molar relationships. Thus, the occlusions of patients with obstructed respiratory function cover the entire spectrum, with Class I malocclusion rather than a Class II malocclusion occurring most frequently.

Similar findings have been observed by the author in a preliminary analysis of the skeletal and dental characteristics of 40 selected, not necessarily representative, patients from the tonsil and adenoid study currently in progress at the Children's Hospital of Pittsburgh. This comprehensive study of the efficacy of tonsillectomy and adenoidectomy surgery was initiated in 1971 by Dr. Jack L. Paradise, a pediatrician, and Dr. Charles D. Bluestone, an otorhinolaryngologist, as a prospective, controlled clinical trial. Each subject met at least one criterion for adenoidectomy—either recurrent otitis media or nasal obstruction attributable to large adenoids, or both—before entry into the study. Then, depending upon whether parental consent for random assignment was granted, each was assigned either randomly or by parental election to surgical or non-surgical groups. (Paradise, '76; Paradise and Bluestone, '76; Bluestone, '79). The average age of the patients was 7 years.

An analysis of the initial lateral radiograph of each patient indicated that 77% of the sample had a Class I molar relationship, 13% had a Class II relationship, and 10% had a Class III relationship. On the average, this group was characterized by excessive anterior facial height and a steep mandibular plane.

The average mandibular plane angle (relative to the Frankfort horizontal plane) was 31.5 degrees, with a range from 20 degrees to 41 degrees. According to the Bolton standards

(Broadbent *et al.*, '75), the mandibular plane angle for the average patient of this age is 25.5 degrees. It should be noted, however, that four of these patients had steep mandibular plane angles and four had mandibular plane angles that fell within the normal range. Thus, the results of this as well as the other clinical studies mentioned indicate that the craniofacial relationships associated with mouth breathing are variable and can be associated with a number of facial patterns.

Retrospective studies of medical histories have also provided information on the relationship between airway problems and craniofacial morphology. For example, Quick and Gundlach ('78) divided a sample of 113 orthodontic patients into two groups: those with a high mandibular plane angle ( $n = 62$ ) and those with a low mandibular plane angle ( $n = 51$ ). The average for the mandibular plane angle in the first group was 38 degrees to the sella-nasion plane (approximately 31 degrees to the Frankfort horizontal plane) and for the second group it was 26 degrees to the sella-nasion plane (approximately 19 degrees to the Frankfort horizontal plane). Analysis of data derived from a medical questionnaire given to each patient showed that there was little difference in the incidence of allergic rhinitis, maxillary sinusitis or deviated nasal septa between the two groups. However, significant differences were found in the incidence of enlarged adenoids or previous adenoidectomy. Nasopharyngeal impairment was noted in 63% of the patients in the long-faced (high angle) group and 23% in the short-faced (low angle) group. The long-faced group also had a significantly higher incidence of symptoms of nasal ob-

struction due to undetermined causes.

Cephalometric analysis of the two groups indicated that the nasopharyngeal cavity was smaller in the long-faced individuals, so that even moderate adenoid enlargement could cause marked symptoms of upper respiratory obstruction in these individuals. Ricketts ('58) has emphasized that the actual adenoid volume is of less importance than the relative size of the space it occupies. Thus, an individual with a small bony nasopharynx is more predisposed to upper respiratory obstruction than is a patient with a large nasopharynx.

Studies of the relationship of airway resistance to facial type are also relevant. Linder-Aronson and Bäckström ('60) compared facial type and type of occlusion in nose breathers and habitual mouth breathers. They noted that children with long narrow faces have greater nasal resistance, on the average, than those with short, wide faces; and that children with a high narrow palate tend to have a greater nasal resistance to air flow than those with a low, broad palate. No direct relationship between mouth breathing and type of occlusion could be found, particularly with regard to overbite and overjet.

In a follow-up study, Linder-Aronson ('63) noted that the mouth-breathing individuals continued to have a significantly higher nasal resistance even after the use of nose drops. In both studies, variations in palatal height were notably greater in the mouth-breathing group than in the nose-breathing group.

These studies seem to indicate that there is a relationship between upper respiratory obstruction and the configuration of the craniofacial structures of a given individual, but that there is no one specific pattern which

can be directly correlated with mouth breathing.

#### EXPERIMENTAL STUDIES OF RESPIRATORY OBSTRUCTION

As in many areas in craniofacial biology, it is often difficult to get precise answers to specific questions regarding biological relationships. The relationship between airway obstruction and craniofacial growth is perhaps best answered by experimental studies, the most definitive of which are those carried out by Harvold, Miller and their associates (Harvold *et al.*, '73, '81; Harvold, '75, '79; Miller, '78; Miller and Vargervik, '78, '79, '81).

In these experiments latex plugs were inserted into the nasal openings of a group of young rhesus monkeys (*Macaca mulatta*). These animals gradually adapted from a pattern of nasal respiration to oral respiration. The first noticeable changes were functional in nature, in that the animals altered their patterns of neuromuscular activity in order to accomplish oral breathing. Individual monkeys met this challenge in different ways. Some of the animals learned to posture their mandible with a downward and backward (retrusive) opening rotation. Some rhythmically lowered and raised their mandibles with each breath. Still others postured their jaw in a downward and forward (protrusive) position, but each in its own way managed to breathe through its mouth.

Morphological changes gradually followed the postural changes. Soft tissue changes occurred first. Notching of the upper lip and grooving of the tongue were seen to gradually develop in different animals. Those animals augmenting the oral airway by pointing the tongue in a forward po-

sition also developed a moderate change in mandibular shape. The tongue itself became long and thin, and an anterior open bite developed. Moderate mandibular changes were also observed in those animals which lowered their mandible for each breath. Dramatic changes in mandibular morphology, particularly at the gonial region and at the chin, were produced in those animals which maintained a lowered mandibular postural position.

Harvold ('79) reported that the distance from nasion to chin increased significantly in mouth-breathing animals, as did the distance from nasion to the hard palate. This indicates that the lowering of the mandible was followed by a downward displacement of the maxilla. The lower border of the mandible became steeper and the gonial angle increased. The most distinct remodeling of the mandible occurred in the ramus, which maintained its normal relationship to the skull even when the chin assumed a lowered position. Harvold speculated that the masticatory muscles attaching the ramus to the skull were relatively unaffected by the respiratory function and continued to maintain a normal relationship to the ramus while the balance of the mandible remodeled in response to the postural change.

What conclusions can be observed from these experimental studies? First, every animal was subjected to the same environmental insult, the blockage of the nasal airway with nasal plugs. However, all animals did not adapt functionally in the same way. The nature of the structural changes produced by insertion of the nasal plugs depended upon the unique neuromuscular adaptation of the individual.

Occlusal effects also varied. Those

animals who rotated their mandible in a posterior and inferior direction developed a Class I skeletal open bite or a Class II malocclusion. Those animals who maintained a more anterior position of the mandible developed a Class III malocclusion.

Thus, a change in breathing pattern led to a variety of skeletal and dental deformities in a species of animal that does not ordinarily develop malocclusions. It is not the change in breathing pattern *per se* which causes the malocclusion. Rather, it is the changes in related functional demands on the craniofacial muscles and their obligatory response.

Specific morphological differences between species are well recognized, even among the various species of primates. However, some broad generalizations comparing the mouth-breathing monkeys to a population of mouth-breathing human patients are appropriate.

As was noted earlier, habitual human mouth breathers also do not present with one specific type of craniofacial morphology. The variety of skeletal and dental configurations observed in these patients may be presumed to be the secondary results of the neuromuscular adjustments required to maintain adequate respiratory function.

Adenoid facies and a steep mandibular plane are frequent findings in patients with upper respiratory obstruction, but they are by no means the only types of adaptation that can occur. Quinn (personal communications, '81) has noted that a low mandibular plane angle may result if the patient postures the tongue over the occlusal surfaces of the teeth in order to maintain an oral airway. This type of patient may even exhibit a deep anterior overbite.

#### ADAPTATIONS FOLLOWING REMOVAL OF NASAL OBSTRUCTION

If there is a direct relationship between nasal obstruction and the course of craniofacial growth, and if this interaction is an expression of the form-function relationship, it can be at least theoretically assumed that the removal of the causative obstruction would initiate a reversal of the change in function. Such a reversal should then be followed by a gradual corrective or positive change in the previously altered craniofacial configuration. Preliminary reports by Harvold *et al.* ('81) seem to indicate that this is actually the case in his experimental animals.

Perhaps the most comprehensive clinical study of the effects of removal of nasal obstructions is that carried out by Linder-Aronson ('75). He followed 41 children who had undergone adenoidectomies for a period of five years postoperatively. The thirty-four children who had switched postoperatively from oral breathing to nasal breathing were compared to 54 normal children. The significant group mean differences found initially between the dentitions and facial skeletons of the operated and control children showed marked change over the postoperative years.

The greatest changes occurred in the dentition and in the sagittal depth of the nasopharynx during the first postoperative year. Linder-Aronson ('70) had noted at the beginning of the study that the mouth breathers had more retroclined upper and lower incisors than did the nose breathers. Other skeletal parameters also changed but more gradually than in the dentition and the nasopharynx.

Using regression analysis, Linder-Aronson ('70) noted correlation between increased nasal resistance and

an increase in the mandibular plane angle. During mouth breathing the retrolingual airway is kept open by increased tonus of the suprahyoid muscles. Infrahyoid and post-vertebral muscles also increased tension to maintain a stable posture and often to rotate the head upward and backward. He also noted that tongue position is lower in mouth breathers.

The mandibular plane angle of the children who had undergone adenoidectomy diminished approximately 4 degrees, twice the reduction found in the control children.

#### CASE REPORTS

The following case reports from private practice illustrate some of the possible relationships between obstructed respiratory function and craniofacial growth. Their growth patterns will be compared to the normal growth standards of Broadbent *et al.* ('75) and by Ricketts' four-point superimposition ('60, '81).

##### *Ideal Face*

An ideal face was constructed, based on an individual from The University of Michigan Elementary and Secondary School Growth Study (Riolo *et al.*, '74). The tracings (Fig. 1) of this subject have been slightly adapted to existing standards of normal growth so that it represents our current concepts of ideal facial growth as developed by the author. This ideal subject has a Class I molar relationship and a balanced facial profile. During the two-year growth period from age nine to eleven years, effective maxillary length (adapted from Harvold, '74) normally increases by 2 mm per year from 85 to 89 mm (Figure 1A). Effective mandibular length increases 6 mm from 105 to 111 mm. The maxillomandibular differential (effective mandibular length minus

effective maxillary length) increases by 1 mm per year, as does lower anterior facial height measured from anterior nasal spine to menton.

In a well-balanced face, point A lies on the nasion perpendicular erected from nasion through the anatomical Frankfort plane (McNamara, '81). Usually this relationship remains constant during the growth period (Figures 1A and B). The orientation of the upper and lower incisors relative to each other remains relatively constant, as does the mandibular plane angle (the mandibular plane angle usually closes only 1 degree every three years (Broadbent *et al.*, '75)). The distance from pogonion to the nasion perpendicular (McNamara, '81) is reduced by 1 mm per year.

*Cranial Base Superimpositions (Fig. 1C).* Superimposing along the basion-nasion plane at the intersection with the pterygomaxillary fissure reveals a downward and forward growth pattern. The facial outline remains relatively constant as the maxilla, mandible and teeth tend to relocate in a downward and forward manner along the facial axis.

*Mandibular Superimposition (Fig. 1D).* Superimposing on the internal structures of the mandible (e.g. the inferior alveolar canal and symphysis) reveals that the condyle is relocated in a superior and posterior direction and resorption of bone occurs along the anterior border of the ramus. The lower first molar erupts vertically and slightly anteriorly, as does the lower incisor.

*Maxillary Superimposition (Fig. 1E).* Superimposing on the internal structures of the maxilla reveals a slight downward and forward movement of the maxillary molars and central incisors relative to the skeletal maxilla.

*Maxillary Displacement (Fig. 1F).*

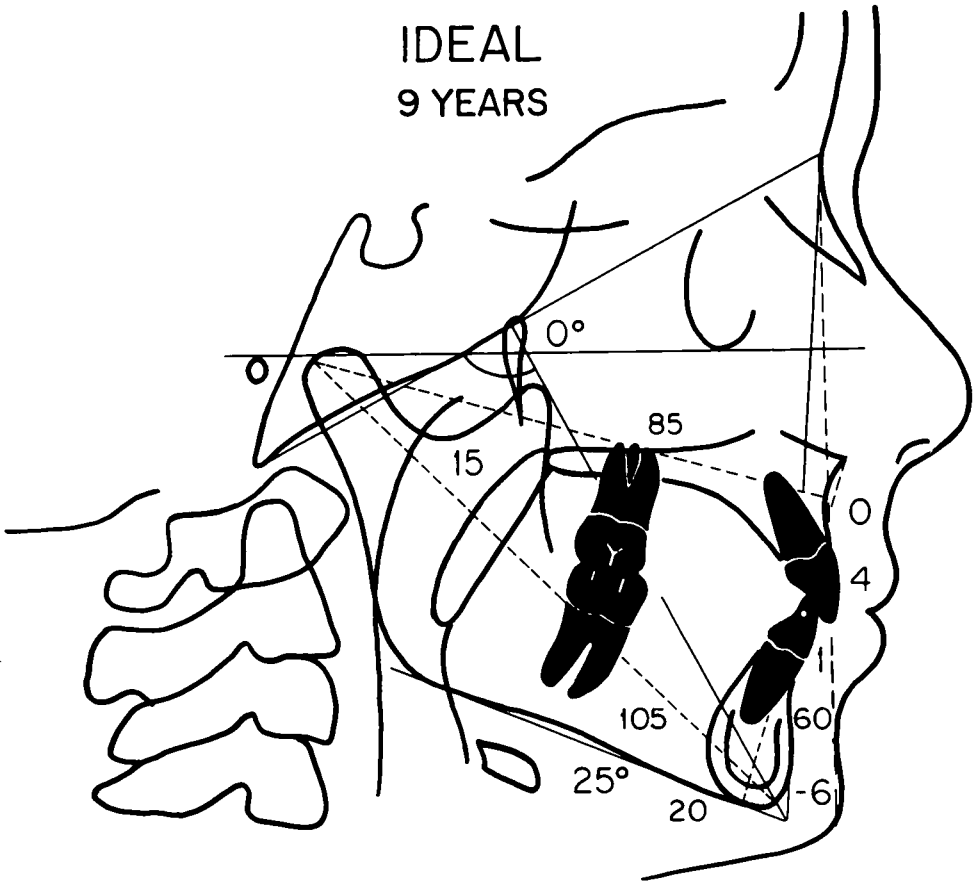


Fig. 1A

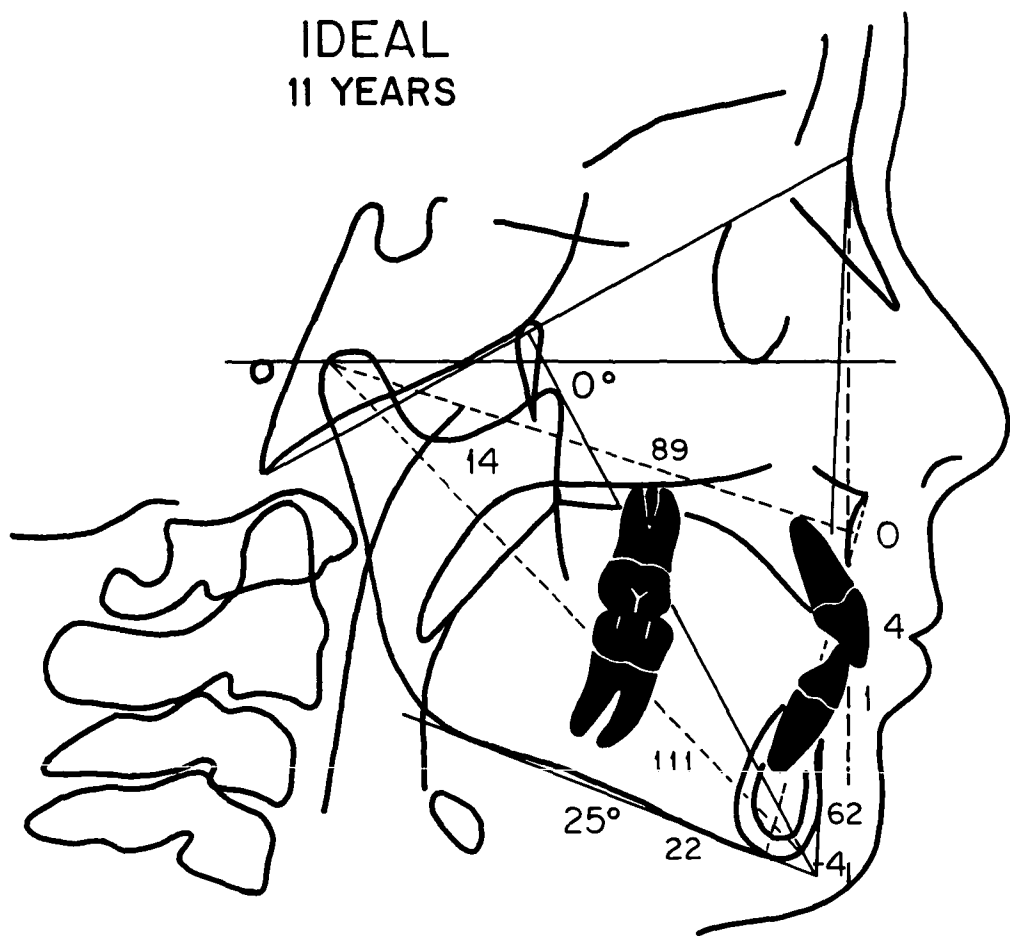


Fig. 1B



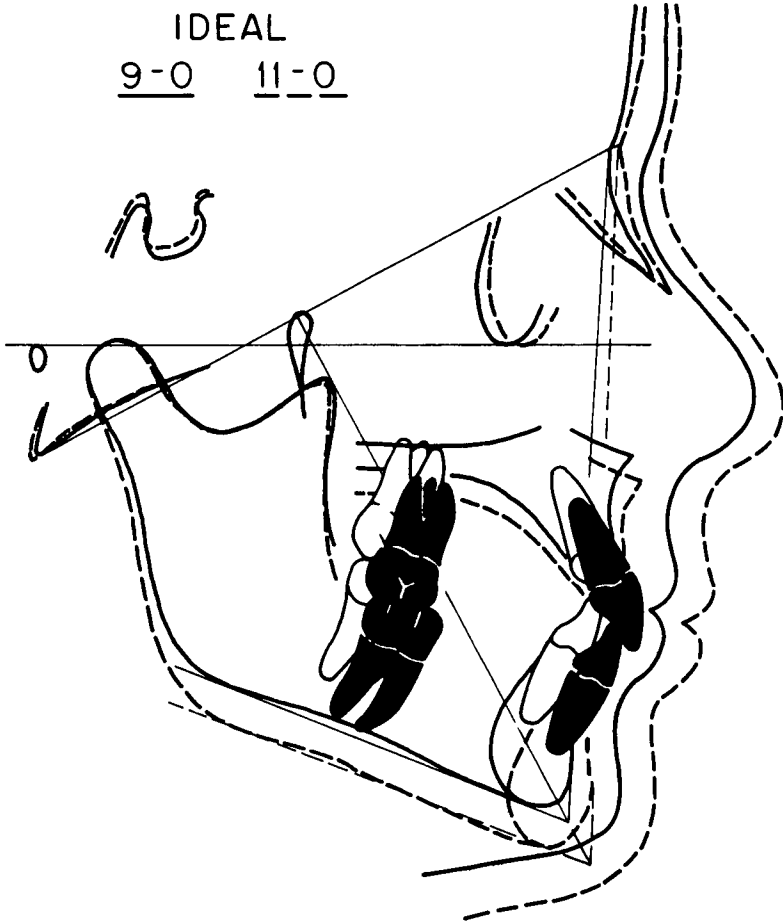
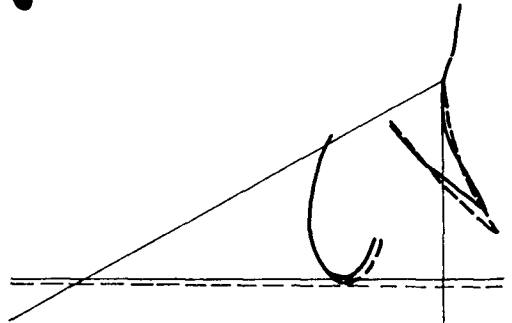

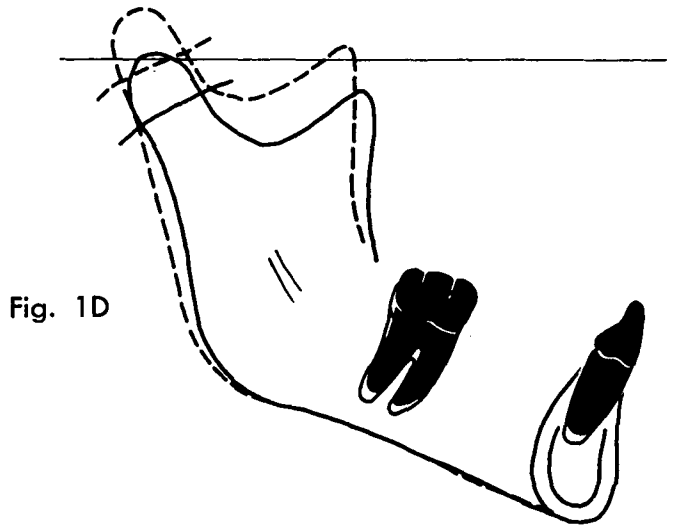


Fig. 1C



The superimposition of serial tracings along the basion-nasion plane at nasion indicates the relative relationship between point A and nasion during the growth period. Most normal growth studies (e.g. Riolo *et al.*, '74; Broadbent *et al.*, '75) indicate that nasion and point A move forward about the same amount during growth. Therefore, in the idealized face the maxilla descends vertically with nasion and point A retaining the same anteroposterior relationship.

#### *Case One: Untreated Airway Obstruction*

This white male presented at age 8 years, 9 months with symptoms of upper airway obstruction. He was relatively short in stature for his age, and his face was long and narrow with a narrow nose and small nostrils, the classic adenoid facies. He had a marginal Class I molar relationship, tending toward Class II with an upper incisor overjet. Crowding was present in both dental arches.

Radiographic examination revealed an adenoidal mass restricting the nasopharyngeal airway between the posterior pharyngeal wall and the posterior aspect of the soft palate to 3 mm (Fig. 2A). The maxillomandibular differential was 20 mm (Fig. 2A), indicating a normal anteroposterior relationship between the upper and lower jaws. The relationship of the maxilla to cranial base structures as indicated by the position of point A relative to the nasion perpendicular was normal.

Excessive vertical height as indicated by measurement from anterior nasal spine to menton was excessive by 6-7 mm. A vertical direction of growth was indicated by the facial axis angle of  $-10$  degrees and a mandibular plane angle of  $35$  degrees. The effect of this disproportionate

vertical dimension was a relative mandibular retrusion.

This patient was referred to an otolaryngologist for an evaluation of his upper respiratory competency. Severe occlusion of the nasopharynx by the adenoidal mass was found, and an adenoidectomy was recommended. However, the parents declined any surgical intervention and no surgical or orthodontic treatment was undertaken.

He was seen again nearly four years later at age 12 years and 3 months. During the intervening time the maxilla had grown 5 mm and the mandible 7 mm, creating a 2 mm increase in the maxillomandibular differential. Anterior facial height increased by 2 mm (Figures 2A and B). Instead of remaining in a constant position relative to cranial base structures, the maxilla had become slightly more retrusive, changing from 1 mm anterior to 1 mm posterior to the nasion perpendicular. The tip of the chin, instead of moving closer to the nasion perpendicular, became more retrognathic (from  $-10$  to  $-13$  mm). The mandibular plane angle increased 1 degree and the facial axis angle opened 1 degree. No change in airway dimension was noted.

*Cranial Base Superimposition* (Fig. 2C). Superimposing along the basion-nasion plane at its intersection with the pterygomaxillary fissure demonstrates the vertical growth that occurred during the  $3\frac{2}{3}$  years between the two examinations. Both the mandibular plane angle and the facial axis angle opened.

*Mandibular Superimposition* (Fig. 2D). Superimposing on the internal structures of the mandible indicates a posterosuperior direction of condylar growth and a relatively greater vertical movement of the lower incisors than the lower molars.

*Maxillary Superimposition (Fig. 2E).* Superimposing on the internal structures of the maxilla indicates a downward and forward migration of the upper molars and, to a lesser extent, of the upper incisors.

*Maxillary Displacement (Fig. 2F).* Superimposition of the two tracings along the basion-nasion plane at nasion indicates that nasion was moved forward slightly farther than point A as the palate descended vertically.

In summary, this patient with chronic upper airway obstruction exhibited a vertical pattern of facial growth. Very little change occurred in either the dentition or in the overall pattern of craniofacial development during the  $3\frac{2}{3}$  year interim. Even with a normal anteroposterior relationship between the maxilla and mandible, the increase in anterior facial height and the slight relative posterior displacement of the maxillary complex caused the face to become more retrognathic.

#### *Case Two: Adenoidectomy*

This white male presented at age 7 years 2 months with a long history of upper airway obstruction. He had suffered numerous episodes of otitis media, experienced a 30% hearing loss during the 3 months prior to his initial visit and was undergoing speech therapy for hyponasal speech. The occlusion was Class I with upper and lower arch length deficiency, bialveolar protrusion, an anterior open bite, and a tendency toward a posterior cross-bite.

Radiographically (Figure 3A) the maxillomandibular differential was 24 mm. This is approximately 5 mm more than expected, indicating a tendency toward a Class III jaw relationship. Lower anterior facial height was at least 10 mm in excess, measuring 69 mm from anterior nasal spine to

menton. The maxilla was retrognathic relative to the cranial base structures, lying 4 mm behind the nasion perpendicular. The mandible was similarly retrognathic due to rotation into a downward and backward position. He had a high mandibular plane angle (31 degrees) and a facial axis of -6 degrees, both also indicative of a vertical growth pattern. His airway measured 2 mm from the posterior surface of the soft palate to the adenoid mass on the posterior pharyngeal wall.

This patient was also referred to an otolaryngologist for an airway evaluation. Examination revealed almost total blockage of the nasopharynx and the posterior choanae by adenoidal tissue. An adenoidectomy was performed two months later.

At the follow-up examination one year later, substantial clinical changes were observed in both facial and dental structures. The patient had no difficulty in breathing through his nose and had switched from habitual oral respiration to nasal respiration. Examination of the intraoral structures revealed a spontaneous closure of the open bite and a normalization of the transverse dimensions between the maxilla and mandible. Radiographic examination indicated that during this one-year period both the maxilla and mandible had increased 3 mm in length, with no change in the maxillomandibular differential (Figs. 3A and C). Lower anterior face height, as measured from anterior nasal spine to menton, *decreased* by 2 mm. The mandibular plane angle (Figs. 3A and B) decreased from 31 degrees to 27 degrees and the growth axis angle decreased from -6 degrees to -4 degrees. Relative to nasion, the maxilla had moved anteriorly by 1 mm and the mandible had moved forward 2 mm. The bialveolar protrusion was unchanged.

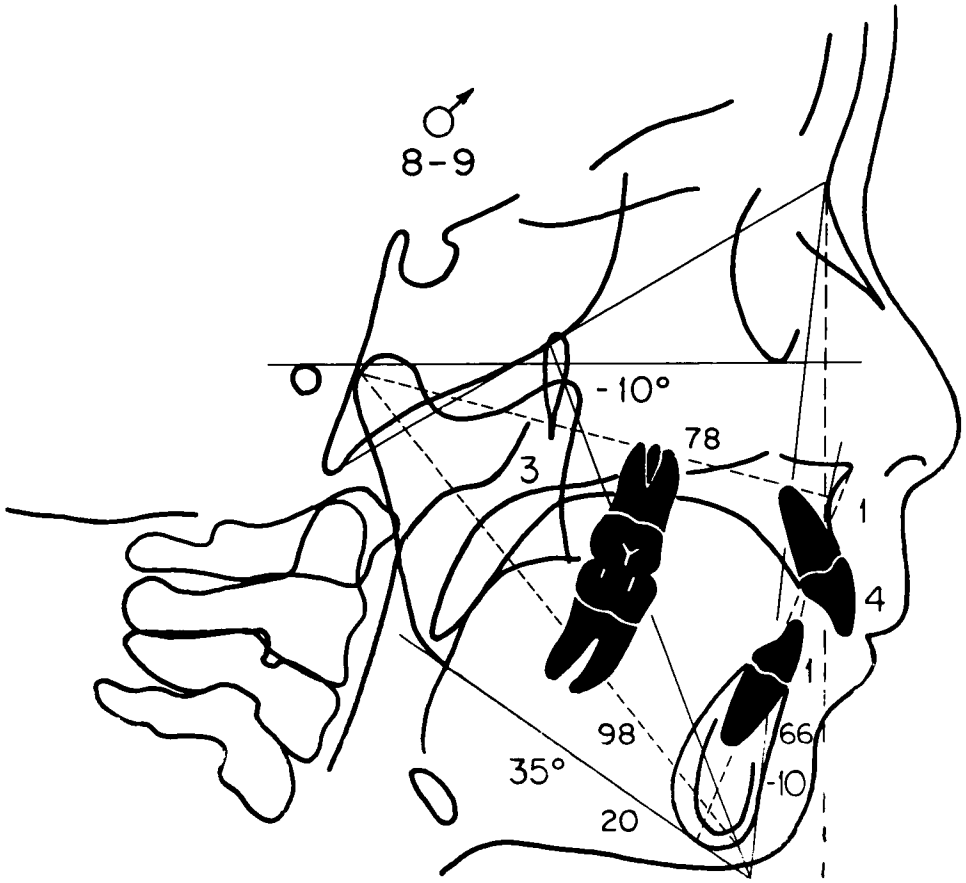


Fig. 2A

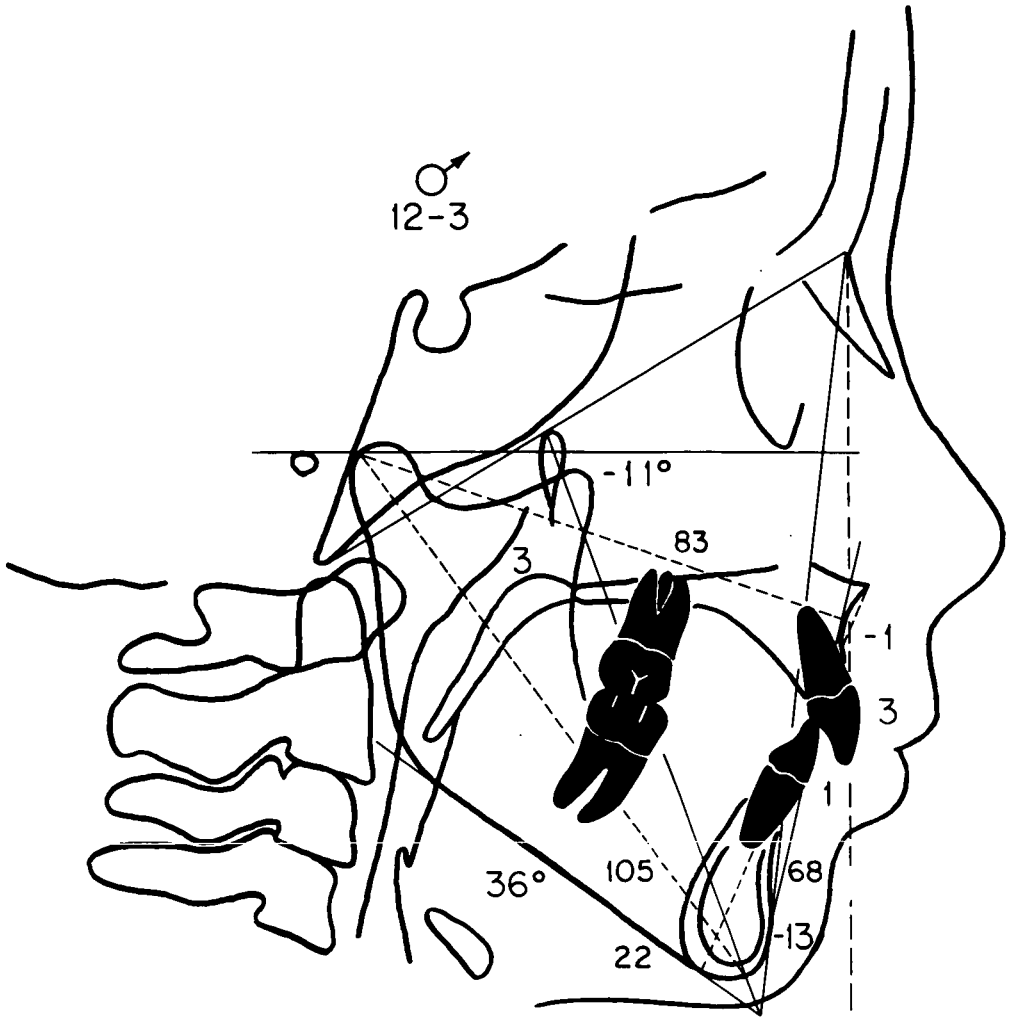


Fig. 2B

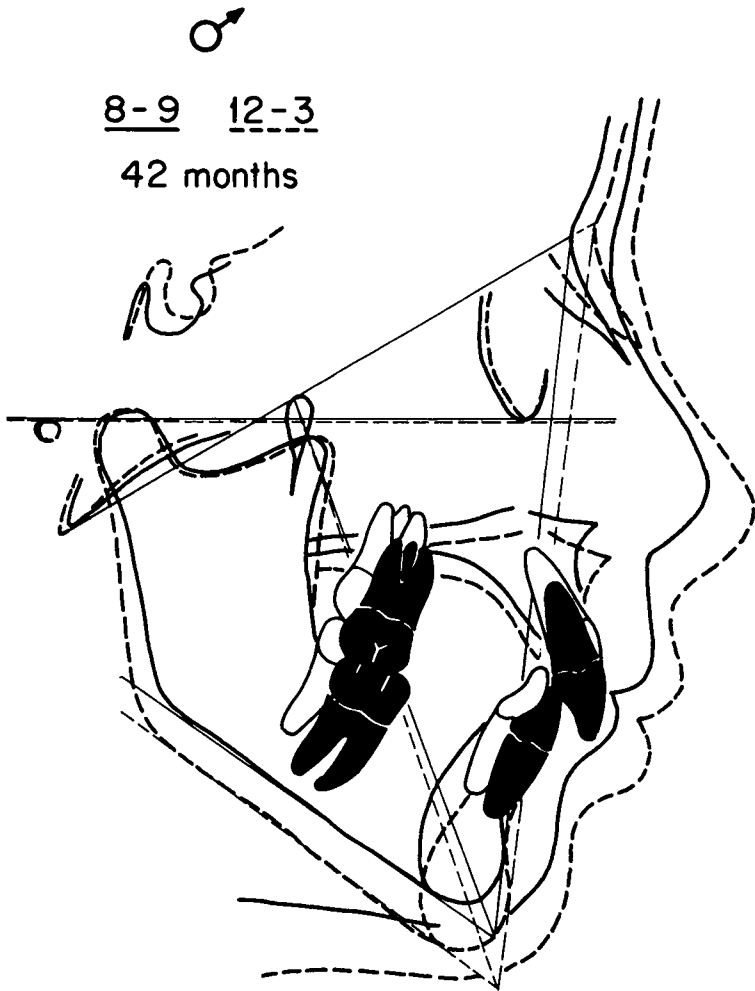


Fig. 2C

Fig. 2D

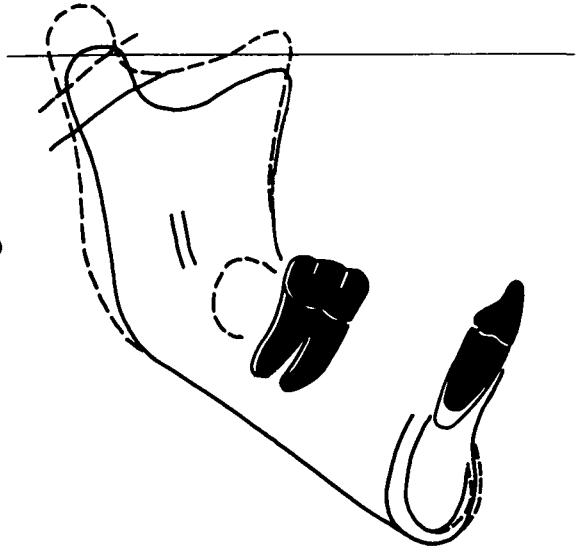


Fig. 2E

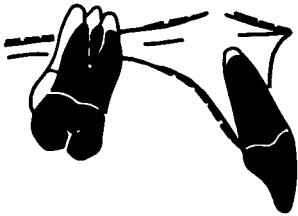
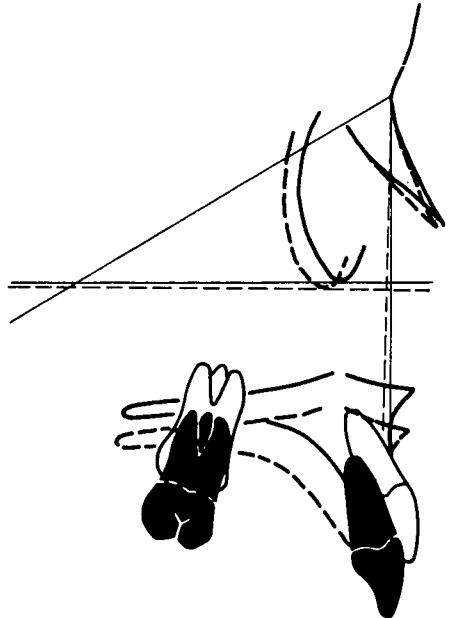


Fig. 2F





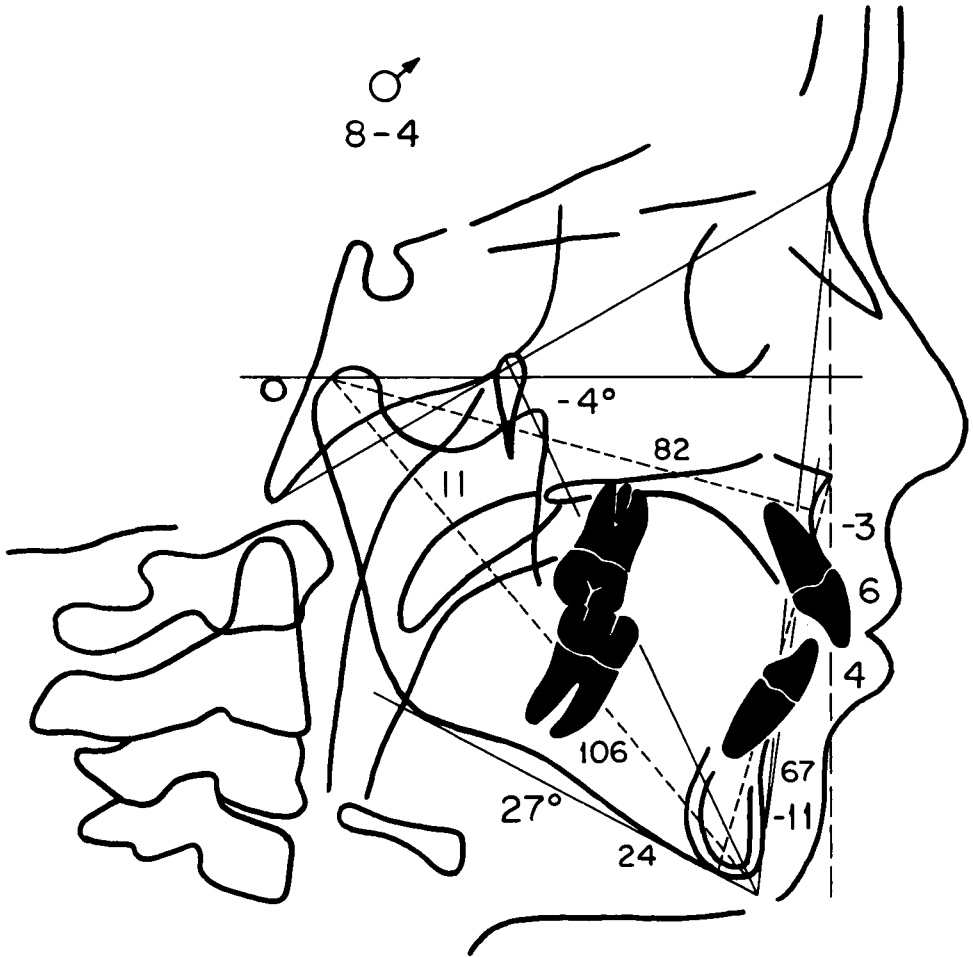


Fig. 3A

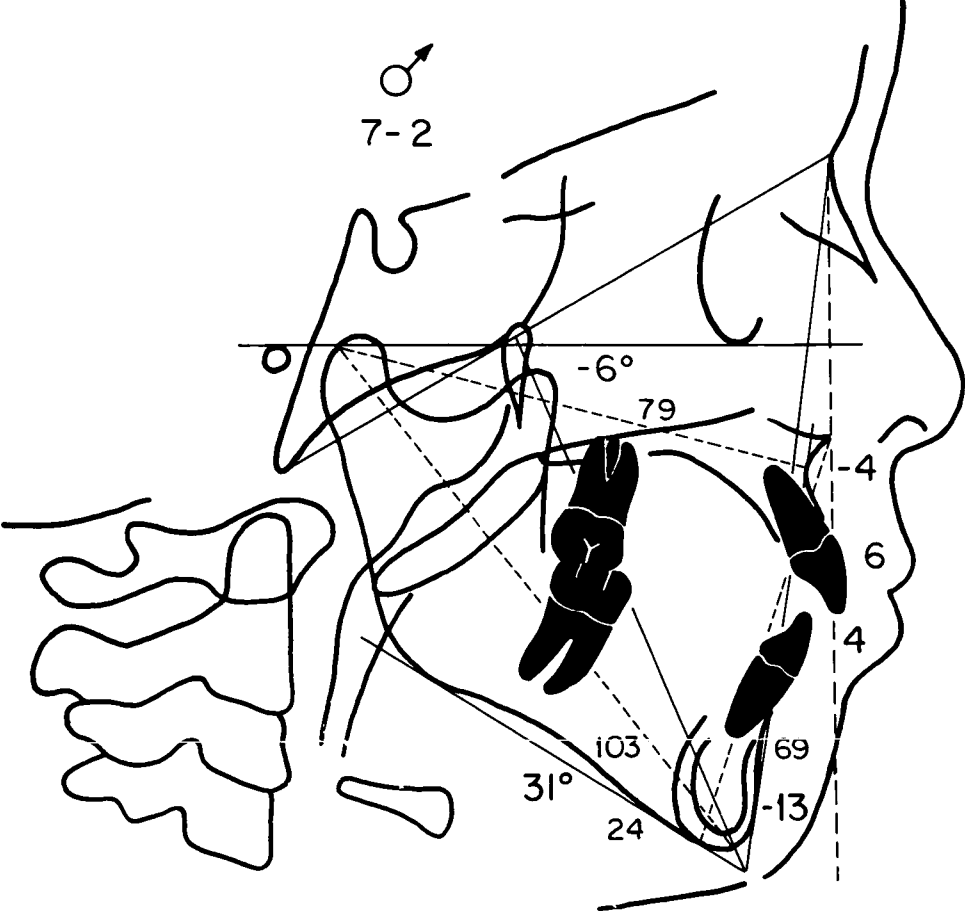


Fig. 3B

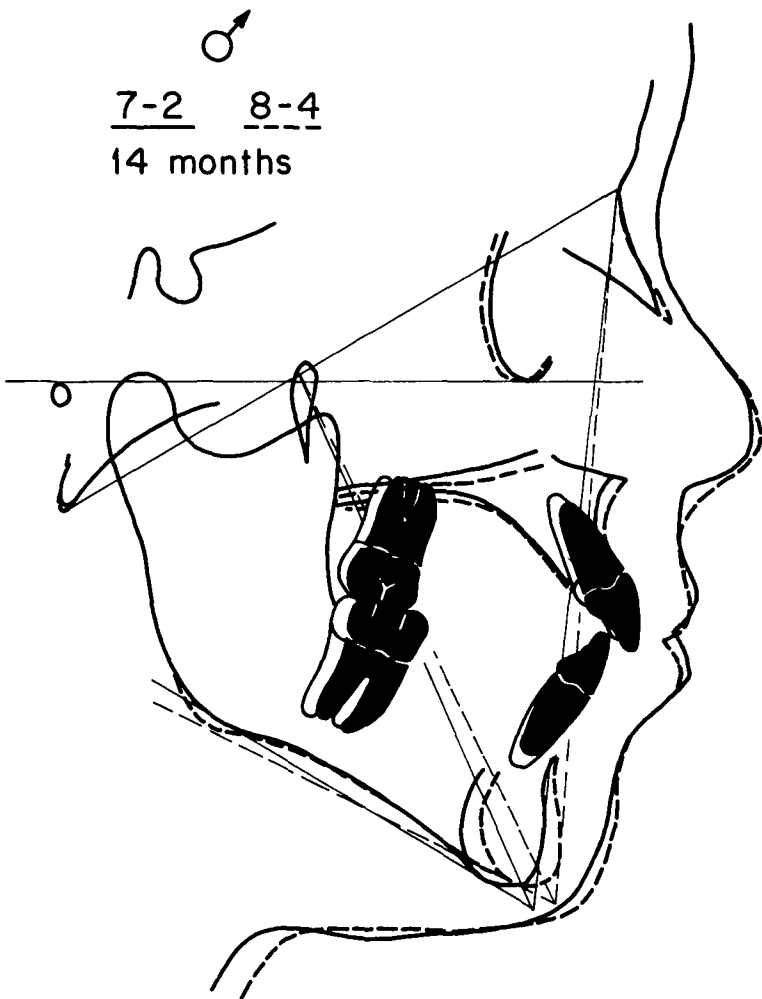


Fig. 3C

Fig. 3D

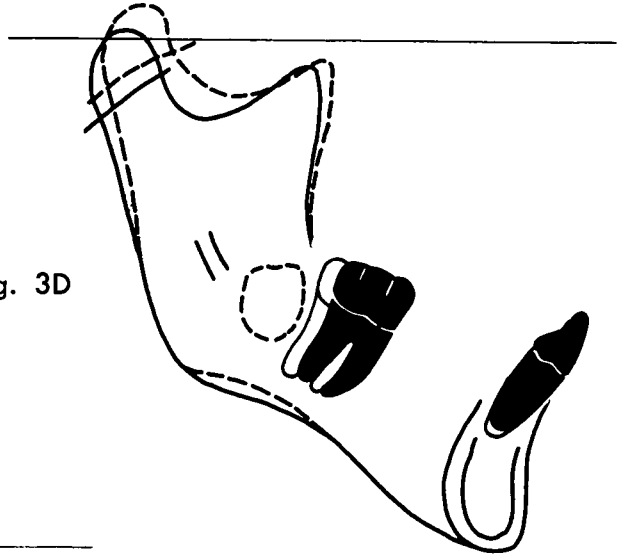
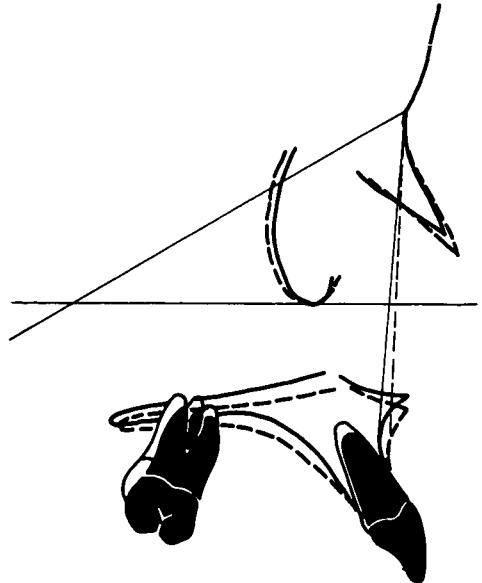


Fig. 3E



Fig. 3F



*Cranial Base Superimposition (Fig. 3C).* Superimposing along the basionasion plane at its intersection with the pterygomaxillary fissure revealed a forward growth pattern. There was an increase in posterior facial height and a slight decrease in anterior facial height (ANS to menton).

*Mandibular Superimposition (Fig. 3D).* Superimposing along the internal structures of the mandible revealed a superoanterior direction of condylar growth with relatively little change in the vertical position of the teeth.

*Maxillary Superimposition (Fig. 3E).* Superimposition on the internal structures of the maxilla revealed very little change in the position of the dentition.

*Maxillary Displacement (Fig. 3F).* Superimposing on the basionasion plane at nasion revealed a forward displacement of the maxilla relative to cranial base structures.

Although this patient was followed for a relatively short period of time, a dramatic 4-degree closure of the mandibular plane angle occurred (the mandibular plane angle normally closes only 1 degree every 3 years). Not only was there an improvement in skeletal and dental relationships in this patient, but his hearing was restored and the quality of his speech improved.

#### *Case Three: Tonsillectomy and Adenoidectomy*

This white male presented at age 8 years and 3 months with a history of upper respiratory disturbances, including otitis media and tonsillitis. He had an end-to-end molar relationship and an anterior open bite. Radiographically (Fig. 4A) he presented with a relatively normal anteroposterior relationship between the max-

illa and mandible (a maxillomandibular differential of 20 mm) and excessive anterior facial height. The maxilla was posterior in relation to cranial base structures (3 mm behind the nasion perpendicular) as was the mandible (18 mm behind the nasion perpendicular). He had a very steep mandibular plane angle of 40 degrees and a facial axis angle of -8 degrees.

This patient was referred to an otolaryngologist for an airway evaluation, after which time an adenotonsillectomy was performed. He was not treated orthodontically.

A follow-up examination 2½ years later revealed that a dramatic change had occurred in the vertical development of the craniofacial complex. As in the previous case, anterior facial height, instead of increasing at the rate of 1 mm a year, had decreased by 2 mm (Figs. 4A and B). The mandibular plane angle decreased from 40 degrees to 34 degrees and the facial axis angle closed forward. The maxilla moved forward 1 mm and the mandible at pogonion moved forward 6 mm.

*Cranial Base Superimposition (Fig. 4C).* Superimposing along the basionasion plane at its intersection with the pterygomaxillary fissure illustrates the increase in posterior facial height and the relative stability of anterior facial height. Although posterior dental relationships remained constant, a closure of the anterior vertical discrepancy was observed.

*Mandibular Superimposition (Fig. 4D).* Superimposing on the internal structures of the mandible revealed a superior direction of condylar growth, indicating a horizontal growth rotation of the mandible.

*Maxillary Superimposition (Fig. 4E).* Superimposing on the internal structures of the maxilla revealed a

forward movement of the molars and incisors, with very little vertical development.

*Maxillary Displacement (Fig. 4F).* Superimposition along the basionasion plane at nasion demonstrates a downward displacement of the maxilla relative to cranial base structures, with little anteroposterior change.

In summary, this patient underwent an adenotonsillectomy for upper airway obstruction. During the 2½ year follow-up period during which no orthodontic treatment was undertaken, there was a dramatic closure of the mandibular plane angle and a lessening of the severe vertical growth pattern seen in the initial radiographs.

#### *Case Four: Late Obstruction of Nasopharynx*

This 12-year-old white male had a submucous cleft of the soft palate. Molars were in a marginal Class I relationship, tending toward Class II. Anteroposterior skeletal relationship was retrusive (Fig. 5A), with a maxillomandibular differential of only 18 mm compared to a normal range of 24-26 mm for a boy his size, and excessive anterior facial height. The maxilla was located in a normal relationship to the cranial base, but there was a moderate mandibular retrusion with bialveolar protrusion. The mandibular plane angle was moderately steep (29 degrees) and the facial axis angle was -3 degrees.

This patient was referred to an otolaryngologist who performed a pharyngeal flap because of velopharyngeal insufficiency.

He was seen again in a follow-up visit 4½ years after the velopharyngeal flap procedure, with no intervening orthodontic treatment. Examination of the patient revealed obvious changes in the relationship of

the various structures of his face. Lower anterior facial height (Figs. 5A and B), which was already excessive at age 12 (70 mm), increased by 16 mm. The anterioposterior relationship between the upper and lower jaws remained retrusive. The mandibular plane angle increased from 26 degrees to 32 degrees and the angle of the growth axis opened even more vertically, from -3 degrees to -9 degrees. An anterior open bite had developed, with marked flaring of the upper incisors.

*Cranial Base Superimposition (Fig. 5C).* Superimposing along the basionasion plane illustrates the severe vertical development that occurred during the 57 months following the velopharyngeal flap procedure. The growth axis angle opened, as did the mandibular plane angle, with a dramatic increase in anterior facial height. The need for compensatory muscle function is indicated by the mass of the mentalis muscle.

*Mandibular Superimposition (Fig. 5D).* Superimposing on the internal structures of the mandible revealed that condylar growth was in a posterosuperior direction. Moderate tooth eruption had also occurred.

*Maxillary Superimposition (Fig. 5E).* Superimposing on the internal structures of the maxilla reveals that primary vertical movement of the dentition has occurred.

*Maxillary Displacement (Fig. 5F).* Superimposition along the basionasion plane at nasion shows the maxilla more posterior relative to cranial base structures.

In contrast to the previous two cases, this patient originally had a restricted airway which was completely closed by surgical intervention, forcing him to become a mouth breather. Presumably, much of the facial distortion that followed the

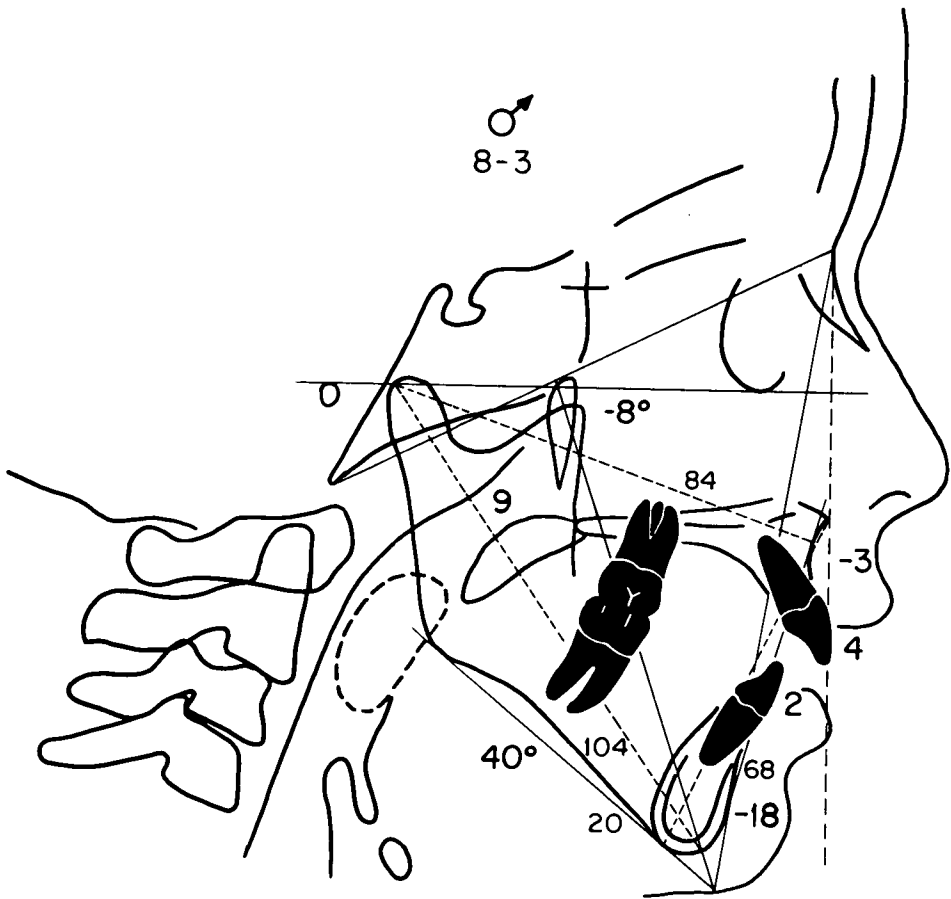


Fig. 4A

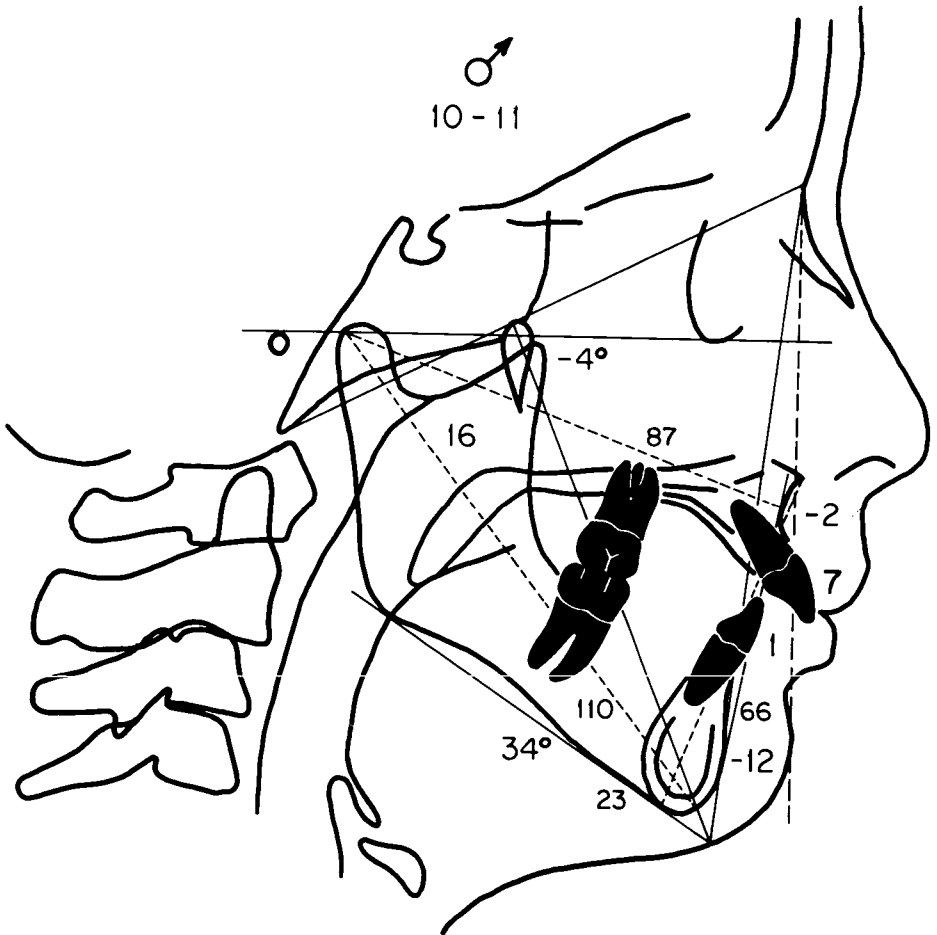


Fig. 4B



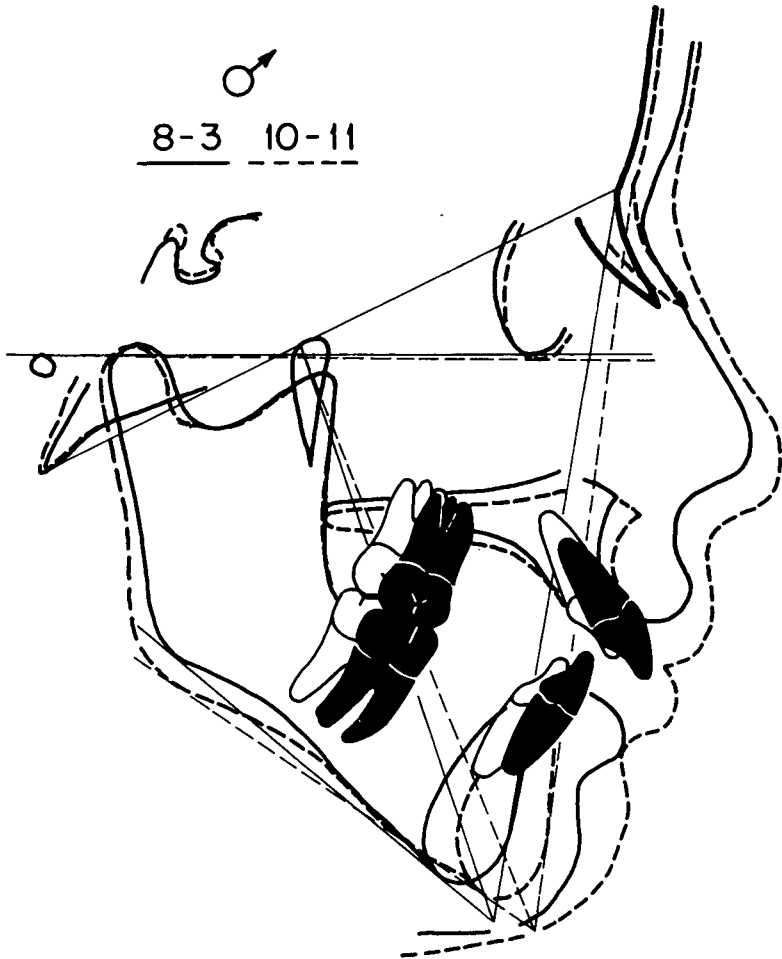


Fig. 4C

Fig. 4D

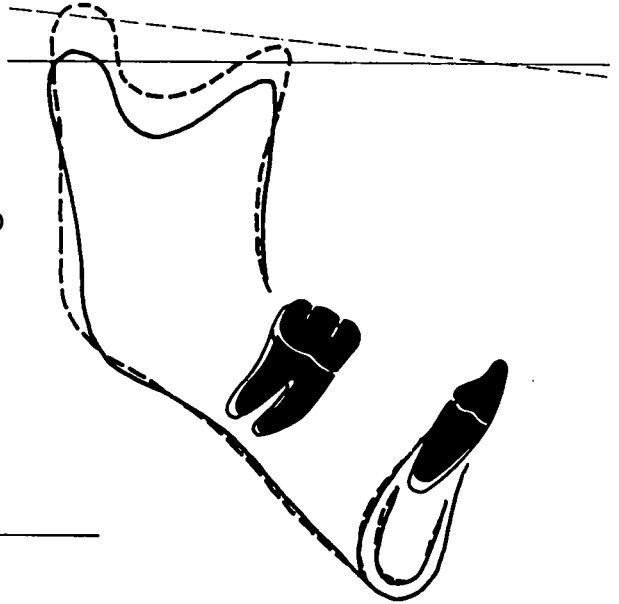
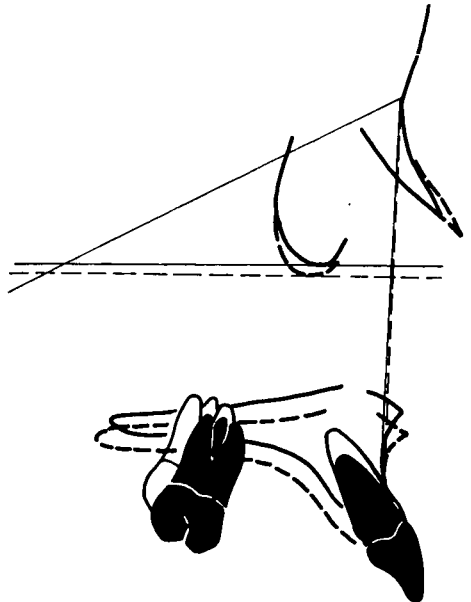


Fig. 4E



Fig. 4F



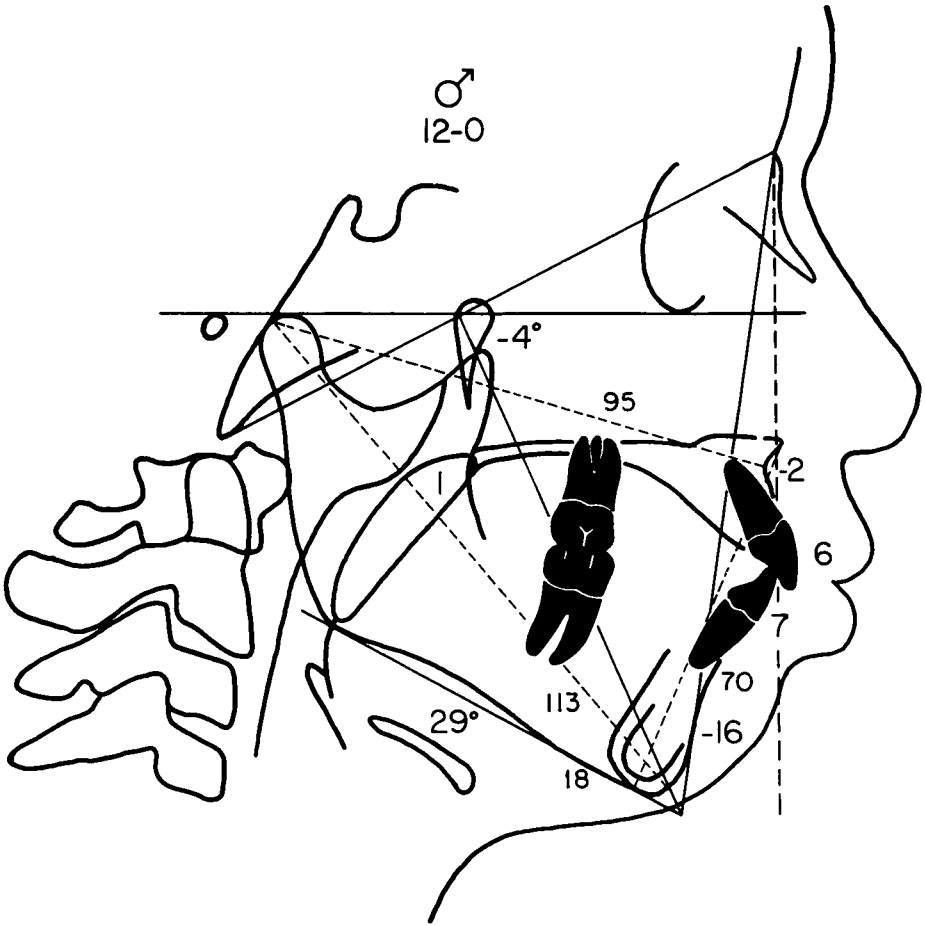


Fig. 5A

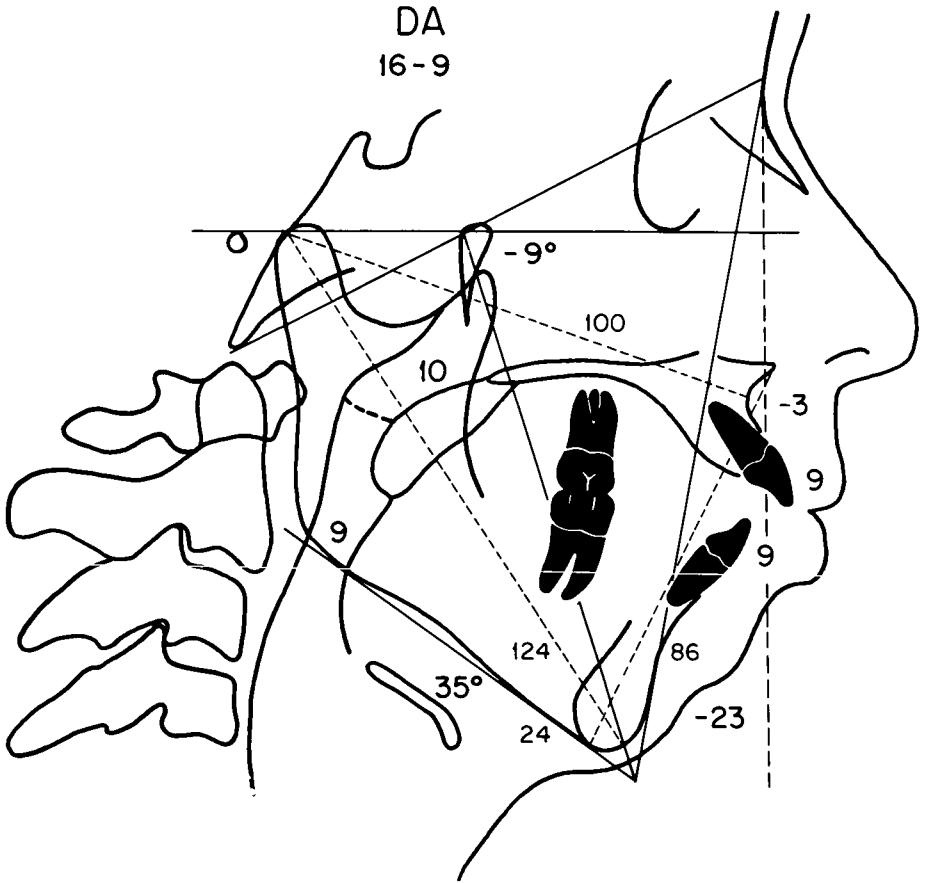


Fig. 5B

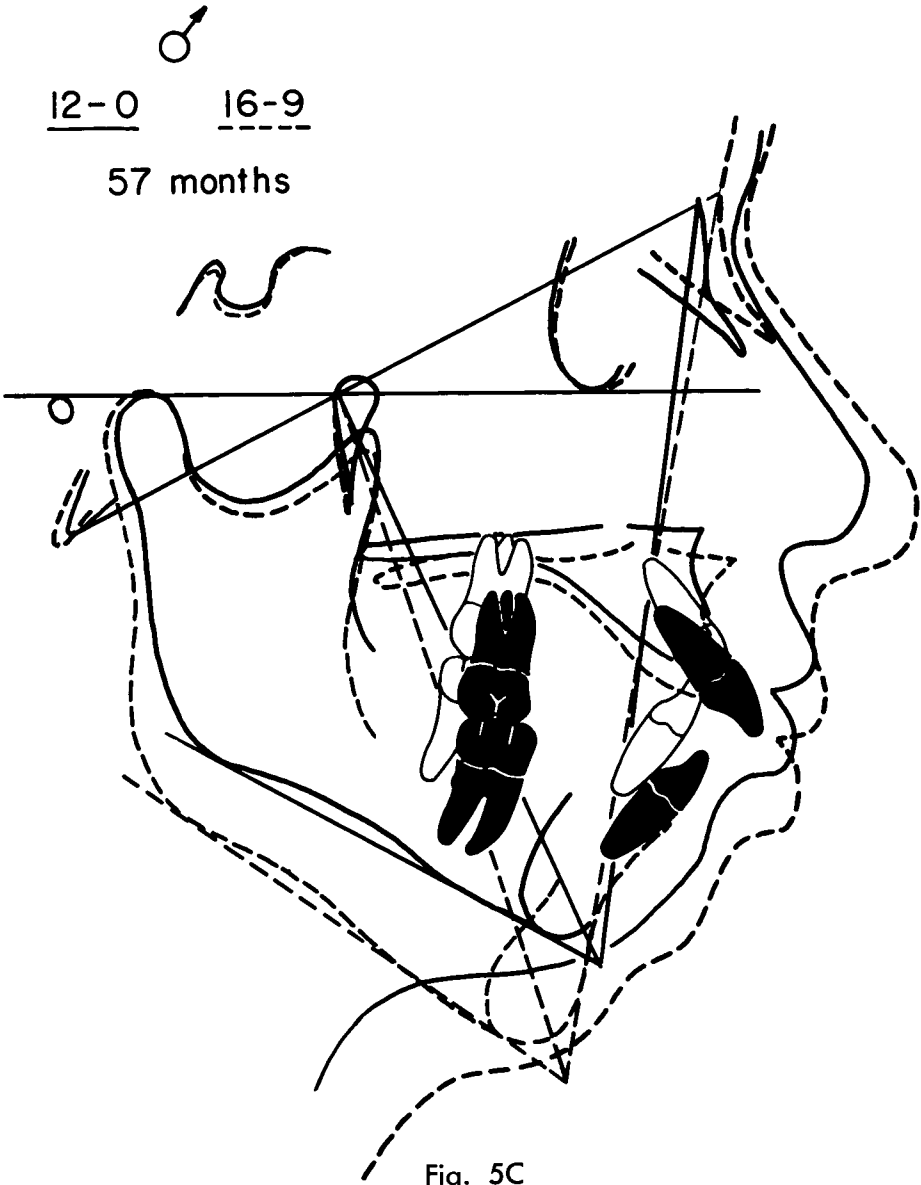


Fig. 5D

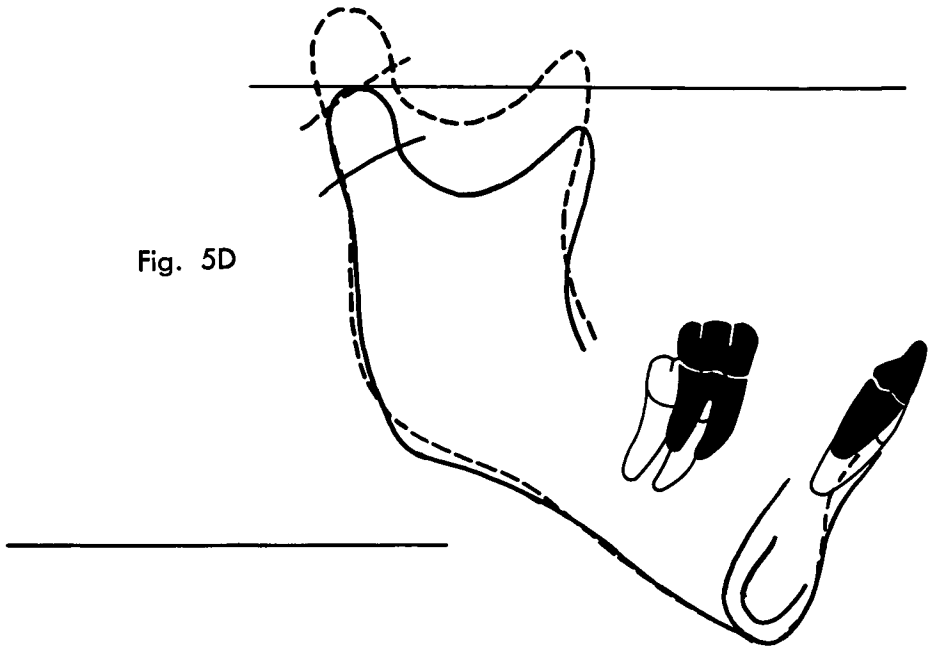


Fig. 5E

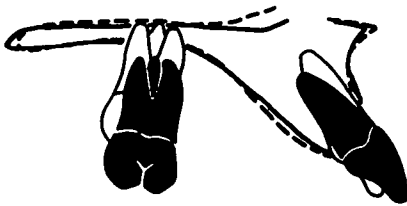
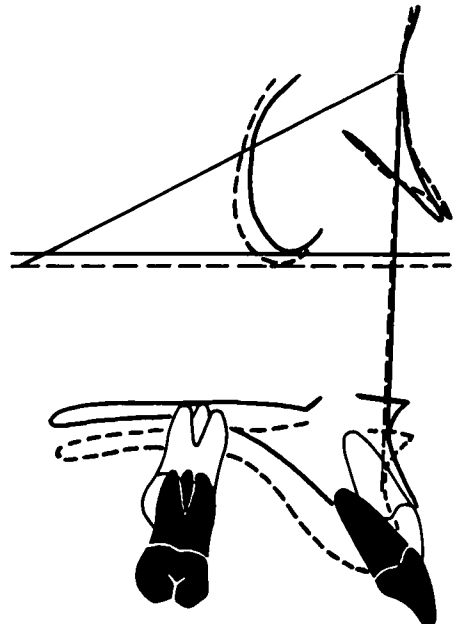


Fig. 5F



pharyngeal flap procedure could be accounted for by the alterations in neuromuscular function which accompanied the adaptation necessary for maintaining an adequate level of oral respiration.

#### SUMMARY AND CONCLUSIONS

The purpose of this paper has been to explore the relationship between upper airway obstruction and craniofacial growth. A review of the literature and of a preliminary study by the author in collaboration with investigators at the Children's Hospital of Pittsburgh indicate both the spectrum of skeletal and dental configurations which are associated with upper airway obstruction and the significant changes in patterns of facial growth which are observed following removal of the obstruction. Four clinical cases were presented. While admittedly only case reports, these do illustrate the potential interaction between alterations in respiratory function and craniofacial growth pattern. The four clinical cases are representative of one type of facial problem which has been classically associated with the mouth-breathing individual; that is a steep mandibular plane. We fully recognize that there are many other manifestations of the environmental problem of upper respiratory obstruction. However, these cases do illustrate the relationship between function and form (i.e. obstruction and deviant facial growth). In order for this relationship to be more fully documented, data from controlled randomized clinical trials must be analyzed.

#### REFERENCES

- Angle, E. H. *Malocclusion of the Teeth*, Ed. 7, S. S. White Dental Mfg. Co., 1907.
- Bluestone, C. D. The role of tonsils and adenoids in the obstruction of respiration. In: *Naso-Respiratory Function and Craniofacial Growth*. J. A. McNamara, Jr. (ed.). Monograph 9, Craniofacial Growth Series, Center for Human Growth and Development, The University of Michigan, Ann Arbor, pp. 251-273, 1979.
- Broadbent, B. H., Sr., B. H. Broadbent, Jr., and W. H. Golden. *Bolton Standards of Dentofacial Developmental Growth*. C. V. Mosby Co., St. Louis, 1975.
- Harvold, E. P. *The Activator in Interceptive Orthodontics*, C. V. Mosby Co., St. Louis, 1974.
- Harvold, E. P. Experiments on mandibular morphogenesis. In: *Determinants of Mandibular Form and Growth*, J. A. McNamara, Jr. (ed.), Monograph 4, Craniofacial Growth Series, Center for Human Growth and Development, The University of Michigan, Ann Arbor, pp. 155-177, 1975.
- Harvold, E. P. Neuromuscular and morphological adaptations in experimentally induced oral respiration. In: *Naso-Respiratory Function and Craniofacial Growth*. J. A. McNamara, Jr. (ed.), Monograph 9, Craniofacial Growth Series, Center for Human Growth and Development, The University of Michigan, Ann Arbor, pp. 149-164, 1979.
- Harvold, E. P., B. S. Tomer, K. Vargervik, and G. Chierici. Primate experiments on oral respiration. *Amer. J. Orthodont.*, in press, 1981.
- Harvold, E. P., K. Vargervik, and G. Chierici. Primate experiments on oral sensation and dental malocclusion. *Amer. J. Orthodont.* 63:494-508, 1973.
- Howard, C. C. Inherent growth and its influence on malocclusion. *J. Amer. Dent. Assoc.* 19:642-648, 1932.
- Huber, R. E. and J. W. Reynolds. A dentofacial study of male students at the University of Michigan in the physical hardening program. *Amer. J. Orthodont. and Oral Surg.* 32:1-21, 1946.
- Johnson, L. R. Habits and their relationship to malocclusion. *J. Amer. Dent. Assoc.* 30: 842-852, 1943.
- Leech, H. L. A clinical analysis of orofacial morphology and behavior of 500 patients attending an upper respiratory research clinic. *Dent. Pract.* 9:57-68, 1958.
- Linder-Aronson, S. Dimensions of face and palate in nose breathers and in habitual breathers. *Odont. Rev.* 14:187-200, 1963.
- Linder-Aronson, S. Adenoids, their effect on mode of breathing and airflow and their relationship characteristics of facial skeleton and the dentition. *Acta. Oto-Laryn. Suppl.* 265:1-132, 1970.
- Linder-Aronson, S. Effects of adenoidectomy on the dentition and facial skeleton over a period of five years. In: *Transactions of the Third International Orthodontic Congress*. J. T. Cook (ed.), C. V. Mosby Co., St. Louis, 1975.

- Linder-Aronson, S. and A. Bäckström. A Comparison Between Mouth and Nose Breathers with Respect to Occlusion and Facial Dimensions. *Odont. Revy.* 11:343, 1960.
- Meyer, W. On adenoid vegetations in the naso-pharyngeal cavity: Their pathology, diagnosis and treatment. *Medico-cherurgical Trans.* (London). 53:191-215, 1872.
- McNamara, J. A., Jr. Components of Class II malocclusion in children 8-10 years of age. *Angle Orthodont.* 51:177, 1981.
- Miller, A. J. Electromyography of craniofacial musculature during oral respiration in the rhesus monkey (*Macaca mulatta*). *Arch. Oral Biol.* 23:145-152, 1978.
- Miller, A. J. and K. Vargervik. Neural control of oral respiration in the rhesus monkey. In: *Muscle Adaptation in the Craniofacial Region*, D. S. Carlson and J. A. McNamara, Jr. (eds.), Monograph 8, Craniofacial Growth Series, Center for Human Growth and Development, The University of Michigan, Ann Arbor, pp. 133-157, 178.
- Miller, A. J. and K. Vargervik. Neuromuscular changes during long-term adaptation of the rhesus monkey to oral respiration. In: *Naso-Respiratory Function and Craniofacial Growth*, J. A. McNamara, Jr. (ed.), Monograph 9, Craniofacial Growth Series, Center for Human Growth and Development, The University of Michigan, Ann Arbor, pp. 1-26, 1979.
- Miller, A. J. and K. Vargervik. Neuromuscular adaptation in experimentally induced oral respiration in the rhesus monkey (*Macaca mulatta*). *Arch. Oral Biol.* 25:579-589, 1980.
- Moore, A. Observations on mouth breathing. *New Zeel. Soc. Periodont. Bull.* 33:9-11, 1972.
- Paradise, J. L. Clinical trials of tonsillectomy and adenoidectomy: Limitations of existing studies and a current effort to evaluate efficacy. *South. Med. J.* 69:1049-1053, 1976.
- Paradise, J. L. and C. D. Bluestone. Toward rational indications for tonsil and adenoid surgery. *Hosp. Pract.* 11:79-87, 1976.
- Quick, C. and K. Gundlach. Adenoid Facies. *Laryngoscope.* 88:327-333, 1978.
- Quinn, G. W. Personal communication, 1981.
- Ricketts, R. M. Respiratory obstructions and their relation to tongue posture. *Cleft Palate Bull.* 8:3, 1958.
- Ricketts, R. M. Respiratory obstruction syndrome. *Amer. J. Orthodont.* 54:495-507, 1968.
- Riolo, M. L., R. E. Moyers, J. A. McNamara, Jr., and W. S. Hunter. *An Atlas of Craniofacial Growth*. Monograph 2, Craniofacial Growth Series, Center for Human Growth and Development, The University of Michigan, Ann Arbor, 1974.
- Thurrow, R. C. The survival factor in orthodontics. In: *Transactions of the Third International Orthodontic Congress* (J. T. Cook, ed.), C. V. Mosby Co., St. Louis, Mo., pp. 17-25, 1975.