

Feature

Cranial Strains and Malocclusion: II. Hyperextension and Superior Vertical Strain

This article has been peer reviewed.

By Gavin A. James, MDS, FDS and Dennis Strokon, DDS

In previous articles^{1,2,3} we discussed the idea of cranial movement continuing throughout life. Arising from this there can be various strains which result in different anatomical configurations. In our most recent article³ we described the cranial, facial and dental sequelae accompanying the strain known as hyperflexion. Hyperflexion and hyperextension strains follow the physiologic and rhythmic flexion/extension movement of the cranium but are labeled as a “strain” because there is an exaggeration of movement either into the flexion phase or the extension phase. Both hyperflexion and hyperextension give rise to their own unique and characteristic cranial, facial and dental features.

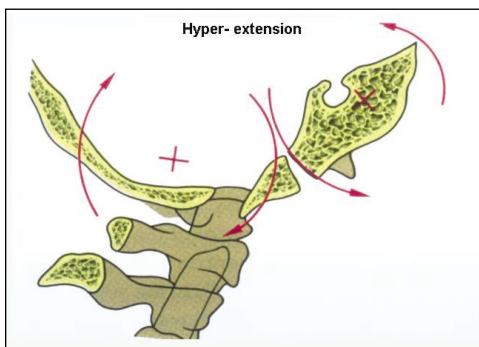


Fig. 1a. Movement of Occiput and Sphenoid in Hyper-extension. Reprinted from *Orthopedic Gnathology*, Hockel, J., Ed. 1983. With permission from Quintessence Publishing Co.

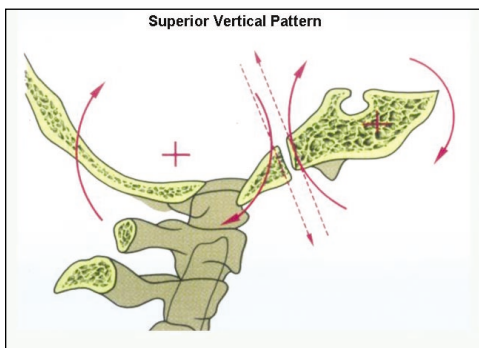


Fig. 1b. Movement of Occiput and Sphenoid in Superior Vertical Strain. Reprinted from *Orthopedic Gnathology*, Hockel, J., Ed. 1983. With permission from Quintessence Publishing Co.

Hyperextension results in several variations of malocclusion, the most common of which is an Angle Class III type with a high Frankfort mandibular plane angle. Another cranial type called a superior vertical strain also predisposes toward an Angle Class III but with a low Frankfort mandibular plane angle. The importance for the practitioner is to recognize what cranial pattern is involved before setting out to treat the Class III patient. Identifying the cranial type will markedly affect our approach to treatment.

Hyperextension-Class III is distinguishable from superior vertical-Class III by observing the patient’s facial and anatomical features as well as the radiographic tracings.

By examining the variation between these two strains at the speno-basilar symphysis it is possible to understand how two distinct facial types arise. The speno-basilar symphysis (S.B.S.) forms the junction of the occiput and the sphenoid at the base of the cranium. Figure 1 is of the occiput and sphenoid viewed from a lateral aspect. In hyperextension (Fig. 1a) the occiput has been displaced in a clockwise rotation. The sphenoid has been displaced in a counter-clockwise direction.

In a superior vertical strain (Fig. 1b) there is a shearing action between the occiput and the sphenoid. The sphenoid is elevated upwards and backwards at the S.B.S. The strain pattern is identified by what happens to the sphenoid at the S.B.S. junction, hence the name superior vertical strain to describe this cranial variation. In the process of the sphenoid elevation there is a clockwise rotation. The occiput is displaced downwards and backwards. It also rotates clockwise.

Figures 2 and 3 are of the full face and profile views of hyperextension and superior vertical strain individuals. It is clear that while they both may have an Angle Class III malocclusion, they are quite different facial types. To identify the origin of these two cranial types it is helpful to use Sutherland’s concept of dividing the cranial base into quadrants.⁴ Figure 4 is of a diagram illustrating the skull base from a vertex aspect. In the case of hyperextension, as the skull lengthens in an anteroposterior direction there is internal rotation of all four quadrants. That is, all the lateral structures of the cranium and face move towards the mid-line.

In the superior vertical strain, the posterior quadrants are also in internal rotation as they are in the hyperextension

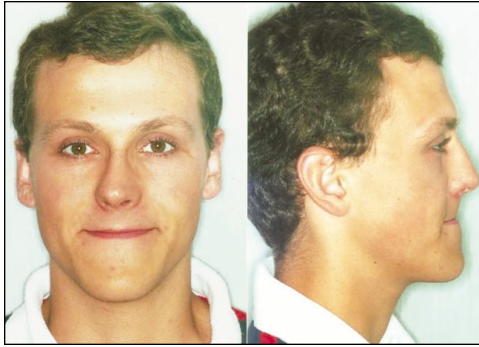

Fig. 2a. Hyperextension – Full face and profile characteristics

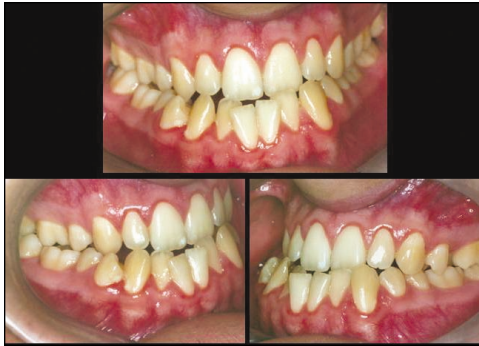

Fig. 2b. Class III malocclusion

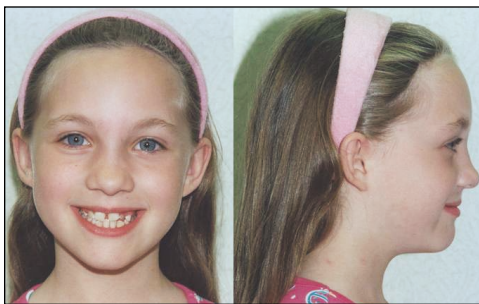

Fig. 3a. Superior Vertical Strain – Full face and profile characteristics

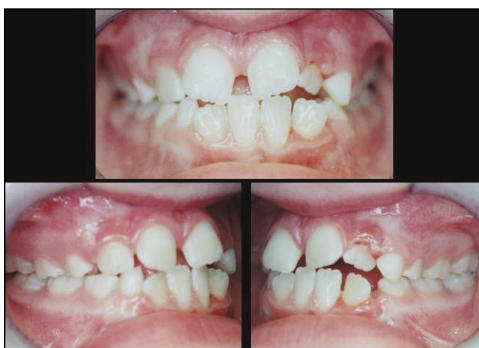

Fig. 3b. Class III malocclusion

example, but the anterior quadrants go into external rotation as well as being drawn up and back. External rotation implies that the anterior cranial structures together with the lateral facial features move away from the mid-line.

In both the hyperextension and superior vertical strain categories the posterior skull is in internal rotation which affects the temporal bones. The temporal bone rotates around the axis running from the petrous tip of the temporal bone to the external auditory meatus (Fig. 5). It is the forward positioning of the glenoid fossae that gives rise to the prognathic tendency of the mandible in both strains. The soft tissue response is that the ears are usually drawn close to the head.

When we examine the two anterior quadrants the facial differences between the two strains can be explained.

Hyperextension – Facial and Dental features

In the hyperextension individual the internal rotation of the anterior part of the skull is reflected in the reduced inter-ocular distance, the narrow nares and the increased curvature of the cranial outline (Fig. 2a). The internal rotation of the sphenoid draws the maxilla inwards and upwards. Another characteristic is a mid-face flatness with lack of development of the malar processes. In profile view (Fig. 2a) there is an obvious increased lower face height and a concave facial profile. The nose may appear large due to the retrusion of the mid-face.

The dental findings in hyperextension reflect the underlying skeletal pattern. There is a reduced overbite or even an open bite, a tendency to reverse overjet and a high narrow palate usually with a unilateral or bilateral crossbite. To accommodate this there is often a lateral functional shift of the mandible (Fig. 2b). Crowding of the teeth in the maxilla may occur because of the deficiency of basal bone both in a lateral and anteroposterior aspect. In the mandible there is often lingual inclination of the teeth with crowding of incisors.

Superior Vertical Strain – Facial and Dental Features

In the superior vertical strain (Fig. 3a) the full-face view appears more balanced since the inter-ocular width and nares are not constricted. The reason for this wider facial appearance is the external rotation of the anterior skull. In profile view (Fig. 3a) if the pattern is mild, the superior vertical strain may not be obvious. Careful examination, however, will often show flatness through the infra-orbital area. The lower face height can be balanced, but occasionally if there is a severe reverse overjet, there is an obvious loss of face height when the teeth are in full occlusion (Fig. 6a, b).

A feature which we have not found in any other strain, is a vertical contour of the frontal bone (Fig. 3a). This results in a bilateral prominent doming of the forehead. It is present to some extent in all superior vertical strain individuals and is a useful diagnostic clue. The external rotation of the frontal bones, plus the upward and backward movement of the sphenoid brings this about.

The dental characteristics of a superior vertical strain are distinctive (Fig. 3b). A deficiency of the premaxillary component results in crowding of the maxillary incisors and cuspids, particularly the lateral incisors. Since the maxillae are externally rotated there is a broad flat palate and a posterior cross bite is therefore unusual. However, there is a deficiency of the premaxilla with possible collapse of the canine width. The lateral incisors may be partially or completely blocked out of the arch. There may be a reverse overjet of one or more incisors reflecting the deficiency of the premaxilla and the retruded position of the maxilla. A lateral shift of the mandible may be present.

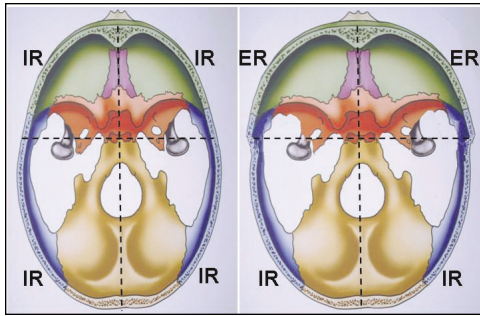


Fig. 4 Comparison of Hyperextension Outline (left) and Superior Vertical Outline (right)
IR = Internal Rotation ER = External Rotation

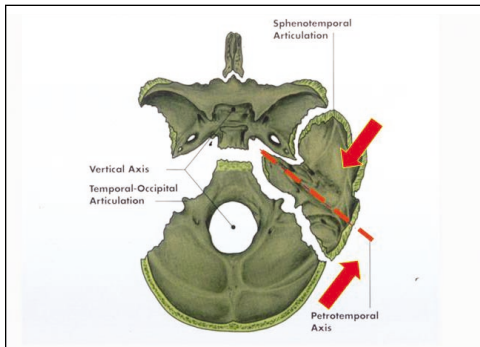


Fig. 5 Vertex view of cranial base showing axis of rotation of temporal bone – arrows indicating internal rotation. Adapted from Orthopedic Gnathology, Hockel, J., Ed.1983. With permission from Quintessence Publishing Co.

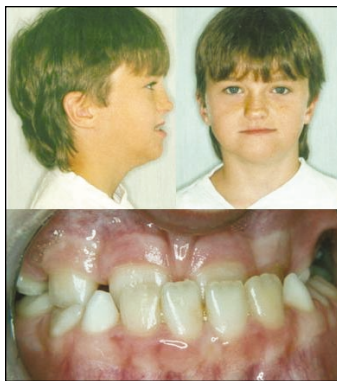

Fig. 6a. Patient demonstrating reverse overjet in Superior vertical strain.

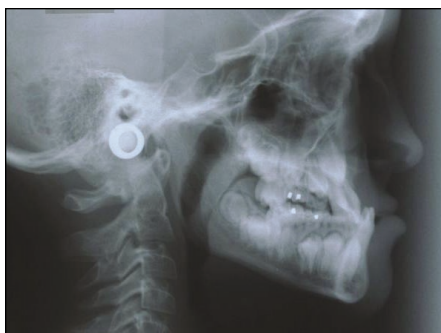

Fig. 6b. Lateral Skull Radiograph of Superior Vertical strain patient showing over-closure.

One occasional anomaly of the superior vertical strain which we have identified is a tendency for the maxillary lateral incisors to be reduced in size or absent. This does not seem to be part of a general oligodontia syndrome, but is limited specifically to the maxillary lateral incisors. Over a four-year period, we have identified 29 individuals as having a superior vertical strain with accompanying lateral incisor anomalies. In these individuals the permanent cuspids often erupt into the missing lateral incisor spaces. When this happens, there is an understandable tendency to substitute the cuspid for the missing lateral incisor and to close spaces by contracting the anterior segment. The consequence of this anterior condensation in a superior vertical strain is contradictory to the needs of the patient and results in further restriction of the cranial movement.

Radiographic Evidence

In both the hyperextension and superior vertical strains the clockwise rotation of the occiput carries the occipital condyles and with them the C1 vertebra distally. Consequently, there is a tendency for an increased forward curvature of the cervical vertebrae with opening of the intervertebral disc spaces anteriorly. Posteriorly the space between the occiput and the transverse process of C1 increases. (Fig. 7a). The maxilla in both patterns is carried upwards and distally. This can be identified by projecting Nasion, pt. A and pt. B onto the Frankfort Horizontal (FH) plane. The relative position of each vertical along the FH plane should be noted. In most cases the pt. A vertical will lie behind the Nasion vertical. Another feature can be a reduction in the size of the pteryopalatine fossae due to the distal positioning of the maxilla. This is particularly evident in the hyperextension group. The cranial base angle (Nasion-Sella-Articulare) is on average 122° reflecting the forward movement of the glenoid fossae. As mentioned, the Frankfort mandibular plane angle can be excessive in the hyperextension case. In both the hyperextension and superior vertical strain there is deficiency in the maxillary apical base. In hyperextension this is due to transverse narrowing. In the superior vertical strain it is due to shortness of the premaxilla.

In the posteroanterior radiograph of a hyperextension individual (Fig. 7b) there can be severe lateral constriction of the nares with the turbinate bones filling almost all the airway space. Deviation of the septum is common. The v-shaped palatal outline is conspicuous. In the superior vertical strain, where the anterior quadrants are externally rotated, nasal blockage does not tend to occur and the palatal outline is flatter.

Before discussing treatment, some general comments are relevant. It has been estimated that the Angle Class III malocclusion is present in approximately 5% of the North American population.⁵ In our experience the hyperextension group is a small portion of this 5% which is fortunate since treatment for these individuals is much more challenging. In contrast, as we have continued to study the cranial strain patterns it has become clear that the superior vertical strain is actually much more common than we originally thought. When there is only a mild tendency present, it is often identified as an Angle Class I. The so-called pseudo Class III or super Class I malocclusion is usually a superior vertical strain and should be treated as such, rather than as a Class I. Early identification of a superior vertical strain can be made in the mixed dentition. Prior to shedding of the mandibular second deciduous molars, there is a full Angle Class I molar relationship usually with a reduced overbite or reverse overjet (Fig. 2b). This should alert the practitioner to the underlying strain pattern. Early identification of this strain is important since it confirms the need for early treatment.

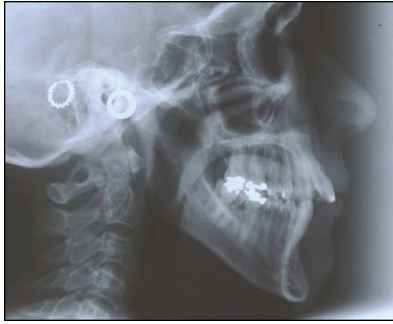

Fig. 7a. Lateral Skull Radiograph of Hyperextension patient.

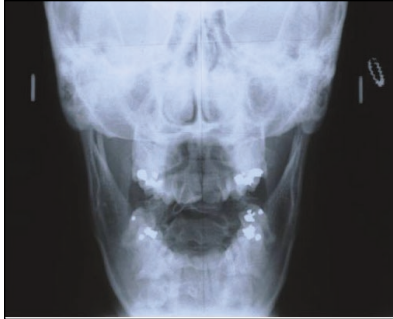


Fig. 7b. Anteroposterior Skull Radiograph of Hyperextension patient.

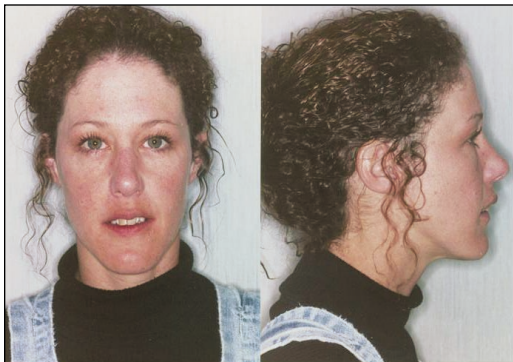

Fig. 7c. Hyperextension - Full face and profile characteristics.

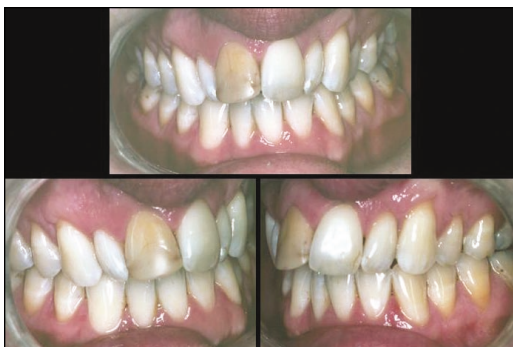

Fig. 7d. Hyperextension patient, Class I molar relationship with Class II tendency.

In both the hyperextension and superior vertical strain patterns the potential for significant worsening of the Class III tendency with adolescence is very real. Late mandibular development can continue in females even up to 16 or 17 years and in males up to 18 or 19 years.

From a functional aspect, hyperextension individuals have a strong tendency to constriction in the upper pharynx and the postnasal area. Mouth breathing together with a low tongue position is common. This constriction can result in a lack of oxygenation and often there is enlargement of the adenoids. These individuals frequently have a history of chronic ear infections possibly with tubes being placed. Chronic maxillary sinus problems are also frequent due to the lack of drainage. The superior vertical strain individuals do not usually have nasal airway blockage or Eustachian tube problems.

In terms of etiology, the hyperextension facial pattern has a hereditary component. The so-called Hapsburg jaw was clearly evident in the Hapsburg royal family over more than 200 years. The absent lateral incisor anomaly in the superior vertical strain also opens speculation as to a hereditary component.

Treatment

Normally, in both strains development of the maxilla with lateral expansion where required and forward movement using Class III elastics or reverse pull facemask is the treatment of choice. In both categories early intervention is beneficial. In the hyperextension group where there is lateral constriction of the palate, rapid palatal expansion has been the conventional orthodontic approach. When the patient is adult, surgical freeing up of the maxilla usually precedes this. Given the need to accommodate cranial movement we no longer consider rapid palatal expansion to be compatible with cranial concepts. The forces generated by rapid palatal expansion mechanics can be damaging to physiological cranial function. We have excellent radiographic and clinical evidence of the effectiveness of very light force in expanding the palate, with a high degree of stability even in adults. To date, we have achieved this with the Advanced Lightwire Functional Appliance. This will be discussed in a later article.

In an adult hyperextension individual extraction of teeth in the mandible, for example first bicusps, may help compensate for the skeletal discrepancy. In a severe case the need for orthognathic surgical procedures may be appropriate. In the superior vertical strain pattern early conservative intervention is very effective and the need for orthognathic surgery is much less likely. Even in an adult superior vertical strain, the existence of cranial flexibility allows for the possibility of significant orthognathic change. The initial treatment for the superior vertical strain is directed towards freeing up and advancing the premaxillary segment. With good cooperation, Class III elastics and even a reverse pull facemask, significant advancement of the mid-face can then be achieved.

An understanding of the patient's cranial type is necessary in making a diagnosis. To rely solely on the Angle classification can be misleading. Patient (7a, b, c, d) illustrates this point. There is an apparent Class II, division 1 malocclusion with a very constricted arch in both the maxilla and mandible. One mandibular incisor had been extracted previously due to crowding. Examination of the face and the radiographs show that this individual is actually a hyperextension cranial strain. The cranial base angle (Nasion-Sella-Articulare) is 118° , i.e. well below the average for Class III individuals. The occiput is rotated clockwise carrying the occipital condyles with it, with the resulting increased curvature of the cervical vertebrae. A Class I molar relationship or even a slight Class II tendency as is here, is not


uncommon in a hyperextension type patient. If treated with Class II mechanics, as the Angle Classification may indicate, this patient would be subject to forces contrary to the cranial predisposition.

The contrast between the hyperextension and superior vertical strain subgroups, both classified as an Angle Class III malocclusion, reveals the strength of the cranial diagnostic approach. Describing both these categories as an Angle Class III malocclusion demonstrates the weakness of the Angle Classification system.

The Angle Classification has been used for almost 100 years and obviously has merit as a description of dental relationships. Unfortunately, squeezing all malocclusions into the restrictions of the Angle system obscures the considerable differences within each class. Every clinician with experience has encountered a malocclusion in which the Angle Classification seems at odds with the facial type. Applying the cranial strain approach can clarify this problem. The cranial strain pattern is logical because it recognizes the realities of the primary etiology. It enables identification of each patient's unique combination of cranial, facial and dental features. The inherent logic of the cranial system suggests that this will eventually replace the Angle Classification as the standard for diagnostic evaluation.

References

1. James, G.A., Strokon, D. "The Significance of Cranial Factors in Diagnosis and Treatment with the Advanced Lightwire Functional Appliance." *Int. J. Ortho.* 14:3:17-23, 2003.
2. James, G.A., Strokon, D. "An Introduction to Cranial Movement and Orthodontics." *Int. J. Ortho.* 16:1:23-26, 2005.
3. James, G.A., Strokon, D. "Cranial Strains and Malocclusion – I. Hyperflexion." *Int. J. Ortho.* 16:2: 25-29, 2005.
4. Sutherland, W. Quoted in *Osteopathy in the Cranial Field*. By Magoun, H. I., 3rd Ed., 1976.
5. Mills, L.F. "Epidemiologic Studies of Occlusion IV. The Prevalence of Malocclusion in a Population of 1,455 School Children." *J. Dent. Res.* 45: 332-336, 1966.



Gavin A. James, MDS, FDS

Dr. James is an Orthodontic Specialist in Barrie, Ontario. A major part of his practice is concerned with the management of temporomandibular joint and craniomandibular disorders. His interest in cranial movement has developed as a part of a more comprehensive examination of the problem of head and neck pain.



Dennis Strokon, DDS

Dr. Strokon is a general dentist in Ottawa, Ontario. He received his dental degree from the University of Western Ontario in 1972. For the past twenty-five years he has taken an interest in treating symptomatic patients using both restorative and orthodontic techniques in his practice. Dr. Strokon and Dr. James lecture on the philosophy, treatment concepts and design of the ALF appliance.