



Available online at www.sciencedirect.com

ScienceDirect

journal homepage: <http://www.kjms-online.com>



Review Article

Non-orthodontic intervention and non-nutritive sucking behaviours: A literature review



Liyana Tanny, Boyen Huang*, Noel Ye Naung, Geoffrey Currie

School of Dentistry and Health Sciences, Charles Sturt University, Australia

Received 26 October 2017; accepted 12 January 2018

Available online 7 February 2018

KEYWORDS

Anterior open bite;
Non-orthodontic
intervention;
Children;
Malocclusion

Abstract Anterior open bite (AOB) is one of the most complex malocclusions to manage. AOB is caused by either by skeletal, genetic or environmental factors. Numerous treatment options are currently utilised to manage AOB. These vary from non-invasive behavioural shaping to orthodontic and surgical interventions. This paper reviews the available orthodontic and non-orthodontic interventions used in the management of AOB. The literature review was carried out using the PubMed search engine from the first of January 2000 to the first of June 2017. Two major keywords (open bite and anterior open bite) were used in addition to 23 minor keywords in the review. AOB is one of the most complex malocclusions to treat with high relapse rates. Long term outcome in treatments of patients with AOB was substantially low. Relapse rates were not taken into consideration for some of the literature reviewed. Despite limitations of the literature, it is recommended that orofacial myofunctional therapy (OMT) and non-orthodontic intervention (NOI) be used in conjunction as an effective treatment option for Anterior Open Bite.

Copyright © 2018, Kaohsiung Medical University. Published by Elsevier Taiwan LLC. This is an open access article under the CC BY-NC-ND license (<http://creativecommons.org/licenses/by-nc-nd/4.0/>).

Introduction

Dental occlusion is simply defined as the relationship between maxillary (upper) and mandibular (lower) teeth when they approach each other during mastication and at resting position. For over a century, issues relating to dental occlusion have been widespread controversies. Such controversies have impacted on the health of the oral cavity at varying degrees, commencing with orthodontic matters during childhood and proceeding to occlusal evaluations of adult patients in general dental practise. Furthermore, the necessity to carry out complex

Conflicts of interest: All authors declare no conflicts of interests.

* Corresponding author. School of Dentistry and Health Sciences, Charles Sturt University, Leeds Parade, Orange, NSW 2800, Australia.

E-mail address: bhuang@csu.edu.au (B. Huang).

<https://doi.org/10.1016/j.kjms.2018.01.006>

1607-551X/Copyright © 2018, Kaohsiung Medical University. Published by Elsevier Taiwan LLC. This is an open access article under the CC BY-NC-ND license (<http://creativecommons.org/licenses/by-nc-nd/4.0/>).

restorative dentistry demands critical thinking to establish optimum results. Restorative dentistry is the restoration of a tooth to or close to its original form by means of metallic, porcelain, synthetic, resin or inlay materials. In addition, patients whose masticatory system has developed pain and dysfunction (temporomandibular disorders, TMDs), there seems to be a high likelihood that their problems would be assessed and managed with some occlusal concept [1].

Anterior open bite (AOB) is defined as the lack of contact between upper and lower anterior (front) teeth when all other teeth are in maximum intercuspation, such as in close contact. Descriptions of this bite vary among different authors and researchers. Several dental practitioners have defined an open bite to be present when there is less than an average overbite, while others believe an edge-to-edge relationship between anterior teeth to be an open bite. In addition, many postulate that a certain degree of openness must be present to classify the bite as open or that there is a lack of overlap of the anterior teeth in centric occlusion [2–4]. Due to varying definitions of open bite, the occurrence of reported cases also varies. In turn, this variation alters statistics representing the frequency of this malocclusion in the population.

The open bite must be evaluated as a deviation in the vertical relationship of the maxillary (upper) and mandibular (lower) dental arches. There should, therefore, be a certain lack of contact in the vertical direction between opposing segments of teeth. The open bite is usually present in the anterior region from the cuspids (canines) to the incisors, hence the name anterior open bite (AOB) [5]. There are two categories of the open bite, skeletal and dental. The craniofacial features constantly linked with the skeletal open bite are increased mandibular plane angle and gonial angle, with a long anterior facial height and an overall increased facial height as well as a retrognathic mandible with palatal plane anteriorly tipped upwards [5–11].

On the other hand, the dental open bite is generally accompanied by normal craniofacial configurations, with incisors that are proclined and under-erupted anterior teeth as well as a normal molar height with thumb-sucking or other oral habits [2]. The majority of open bites contain both dental and skeletal characteristics [2]. While dental open bites can be treated with orthodontic or behaviour shaping strategies, the skeletal open bite requires a more complex approach combining orthodontic and orthognathic surgical procedures to reach function, aesthetics and stability [12,13] (Fig. 1).

Given the above definitions, the prevalence of AOB differs substantially among studies depending on how authors describe this abnormal occlusion. The word 'malocclusion' can be subjective, as the notion of 'ideal' occlusion is a rare incident and hence slight occlusal variations do not necessarily lead to specific health risks. Having said that, the anterior open bite is described as abnormal as it impacts on the patient's function, speech, mastication, future dental health risks and aesthetics [14]. Reported prevalence in the population is estimated to range from 1.5% to 11% [15–17]. Numerous factors affect the open bite, including age, gender, non-nutritive sucking habits, to mention a few. Factors such as age can impact on prevalence, as sucking habits and oral function mature with age. At the age of six, the AOB presents as low as 4.2%, while at age 14 years the

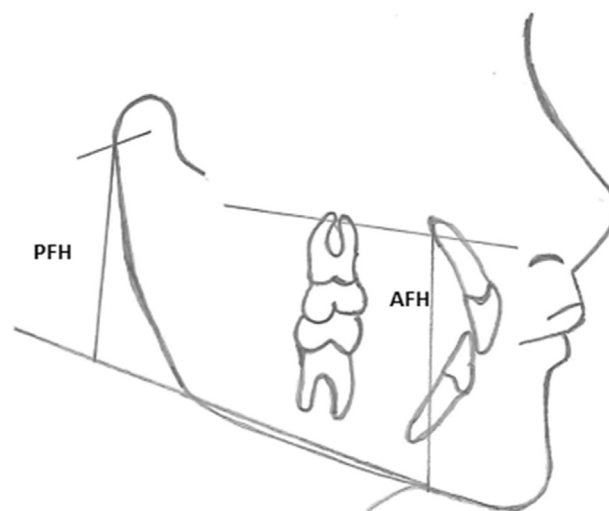


Figure 1. AFH: Anterior facial height, PFH: Posterior facial height.

prevalence declines to 2% [15]. In the American population, the prevalence detected was ethnicity-dependent with 3.5% present in Caucasian children while 16.5% in Afro-descendent children. Although the prevalence is low, the necessity to treat this malocclusion is very common with around 17% of orthodontic cases having AOB [17]. Thus dental practitioners must regard this malocclusion with care and address it accordingly [15,17].

Several etiologic factors linked with open bite have been proposed. These include genetic, anatomic and environmental factors. When taking the genetic factors into consideration, the open bite is mainly associated with patients' unfavourable growth capacity and heredity [11,18,19]. A detailed family history as well as radiographic and cephalometric analyses are hence necessary to identify whether there is a genetic factor present [20]. The anatomic factor includes size and position of the tongue has been suggested to affect both the dental and skeletal factors [21]. Furthermore, macroglossia, which is an unusually enlarged tongue, has also been proposed to influence AOB [22]. Reports identify that in individuals with AOB, a strong relationship between the angle of the mandible plane, mandibular ramus height, or the maxillary anteroposterior dimension and front section of the dorsal surface of the tongue movement during swallowing [23]. In addition, several anatomic ailments including enlarged tonsils and/or adenoids, swollen nasal turbinates and nasal septums that are deviated may impact on normal upper respiratory nasal function [24]. Consequently, due to upper airway obstruction, mouth-breathing can take place and, in turn lead to AOB; however, a direct link has not yet been proven [25]. Moreover, the resorption of the mandibular condyle has similarly been recognised as aetologic of AOB. There are several systemic and local conditions that result in mandibular condylar resorption. Systemic connective tissue or autoimmune diseases that can produce condylar resorption include psoriatic arthritis, systemic lupus erythematosus, rheumatoid arthritis, scleroderma, ankylosing spondylitis and Sögren syndrome [26]. On the other hand, local factors include infection, osteoarthritis, reactive arthritis, traumatic injuries and avascular necrosis [26].

In contrast, environmental factors such as thumb and finger sucking, forward posture of tongue and tongue thrust have all been suggested to cause AOB [27–30]. Digit sucking had been said to cause an asymmetrical anterior open bite that is worst on the side where the digit sucking takes place. Having said that, not all thumb or finger suckers acquire an AOB; this is more dependent on frequency and duration of the habit [31]. It has been reported that those who suck for duration of 6 h or longer a day leads to considerable malocclusions [27,31]. A forward tongue posture, which describes the state where the tongue rests between the incisors may lead to obstruction of incisor eruption can cause AOB [28,29,31]. In addition, tongue thrust, whereby the tongue moves forward during deglutition can also lead to AOB [30,31].

Due to the above mentioned aetiologic factors, several treatment options have been proposed for treatment and management of the AOB malocclusion. The treatment options include behavioural modifications to eradicate oral habits or abnormal functions [32–38], orthodontic treatment that involves extruding the anterior teeth or intruding the molars [39–44], and surgical treatment of the basal bones [41,42,44–46]. The only agreement that seems to be current is that treatment of the anterior open bite is demanding and has high rates of relapse [8,17,35,47].

Orofacial Myofunctional therapy is utilised to modify function and is composed of a set of exercises that re-educate orofacial muscles in swallowing, speech and resting posture [11,48,49]. It has been suggested that involuntary activities such as tongue posture habits are difficult to modify while voluntary movements such as swallowing and speech are much simpler to alter using orofacial myofunctional exercises [48,50].

Sessions of the myofunctional therapy exercises include strengthening tongue and lip musculature, modifying the swallowing process and coordinating the total swallowing movement and practising conscious and unconscious habit formation [51] as well as resting posture of the tongue [52].

Other mechanisms that correct functional habits include the prevention of the tongue to rest on the anterior teeth [53]. These are best identified as lingual or palatal cribs [11] and spurs [54,55]. Cribs are usually attached to the palatal surface of the upper arch and allow the sucking to stop as they act as a digit-inhibiting tool [16,35,56–58]. The palatal or lingual cribs are also designed to prevent the tongue from resting on the teeth and in turn correcting the AOB [11]. However, these structures are smooth and purposefully enable the tongue to rest on them so that in several cases it may block the functional restoration of the tongue. Hence the tongue then returns to its original position resulting in relapse of anterior open bite [59].

This change of tongue position modifies sensory perception by the brain, thus creating a new motor response which can be permanently imprinted by the brain [54,55]. This clarifies the permanent change in tongue posture created by spurs and resulting in AOB treatment stability [54,55].

The degree of testimony on long-term outcomes of patient's treatment with AOB was substantially low, and the literatures incorporated in this review were primarily illustrative. Eminent diversity implies that an array of treatment effects and long-term outcomes of open-bite therapy can be anticipated. Article appraisal summaries

must therefore be deciphered with precaution. Nonetheless, this uncontrolled sample symbolises the best evidence to date and could serve as a starting point for future studies with more meticulous designs.

In terms of the research methodologies, all studies displayed various methodologies in AOB treatment/management [2,33–35,38,40,41,45–47,49,51,60–63]. Meral and Yüksel [62] included radiographic assessment with the approach of utilising a magnetic device and using a small sample size. The use of the magnetic device in conjunction with the bite block has demonstrated very effective AOB treatment throughout history. However, they had not mentioned behavioural shaping to eliminate the AOB. While Cayley, Tindall [51] had introduced electropalatographic and cephalometric assessment for AOB treatment, with the methodology being solely based on behavioural changes of a small sample of children. Both studies had not cited relapse possibilities in regarding to treatment nor had targeted younger children where the presence of oral habits such as nutritive sucking is prevalent.

Furthermore, AOB has long been regarded as a complex malocclusion to treat/manage with correction being highly prone to relapse [11,41,64]. This is due to a multifactorial aetiology, involving skeletal, dental, neurologic, habitual and respiratory [11,40,64]. There has not yet been established an agreement as to the best treatment option for this malocclusion; which can be corrected through shifting teeth in the alveolar bone by orthodontic apparatus [40,61]; through behaviour-shaping appliances that prevent thumb-sucking and tongue thrusting [34,35,63]; orofacial myofunctional therapy to modify tongue position [38]; through surgery by means of extractions or through combining both orthodontic and surgery methods [41,46].

The two promising studies that outlined nonsurgical and non-orthodontic intervention in the treatment of AOB were by Van Dyck, Dekeyser [38] and Huang, Lejarraga [34]. Both studies have been presented as pilot studies using a small sample size. Huang et al. [34] targeted children between the age 4–12 years and presented with dental habits and utilised stomahesive wafers as non-orthodontic therapy while Dyck et al. [38] employed orofacial myofunctional treatment as a principal treatment option with intervention questionnaires which played an important role in coaching the tongue to its correct position.

Table 1 Key words used in the MEDLINE database (PubMed).

Principle Keywords:	"Anterior open bite", "open bite"
Minor words:	"Appliance", "Appliance therapy", "Bottle-feeding", "Breastfeeding", "Breast-feeding", "digit sucking", "Feeding", "finger sucking", "Malocclusion", "Management", "Myofunctional therapy", "Non-nutritive", "Oral habits", "Pacifier", "Passive correction", "Stomatognathic", "Stomatognathic system", "sucking", "Therapy", "Thumb", "Thumb-sucking", "Tongue-thrust", "Treatment",

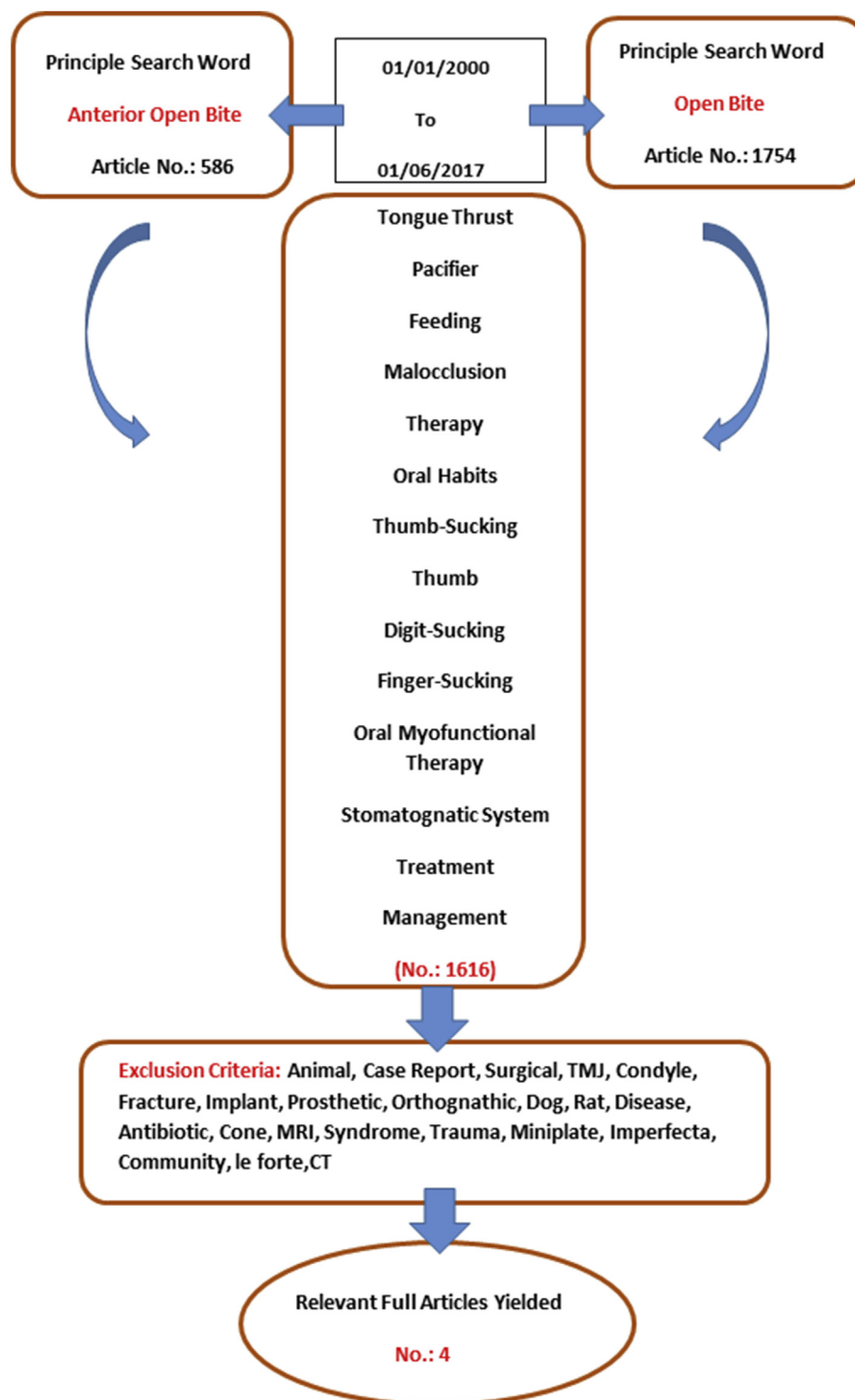


Figure 2. Search database in PubMed.

Material and methods

The systematic review (Table 1) was carried out based on the search engine MEDLINE database (Pubmed) and limited to the years between 01/01/2000 and 01/06/2017.

During the search procedure, one principle word was combined with each of the minor words and as a result 2067 articles were collected. After applying the inclusion and exclusion criteria in Pubmed to the topic, a total of 240 articles were collected. The other articles included those

not in English, non-published and did not fit the selective criteria. A total of four articles were deemed relevant following abstract and full article review. Articles that involved clinical trials were taken into consideration, in addition to articles involving treatment with NOI, OMT, or a combination of both. Duplicated abstracts were excluded from the review (Fig. 2).

Results

The literature yielded a total of nine articles that were relevant to the search criteria. Following further application of the selection criteria on the full articles, a total of four articles were deemed relevant (Table 2).

Among the above mentioned articles, only four met the selection criteria. The other articles were excluded due to the age group of the study and the language used other than English. The four selected articles showed considerable difference in the methodology and application of clinical management. In addition, there were difference in study design, sample size, and method of statistical analysis. However, all the selected articles provided a result for treatment of anterior open bit without any orthodontics or orthognathic intervention as shown in Table 3.

Huang et al. [34] utilised NOI in the management of AOB. NOI included the use of orofacial myofunctional therapy and a stomahesive wafer that was placed on the incisive papilla to guide the tongue tip to rest in that position. The age range of participants was 4–12 years old. While Van Dyck et al. [38] involved participants from 7 to 10 years approximately and assigned them into two groups; OMT or non-OMT. The OMT group involved guiding the tongue posture during rest, mastication and swallowing.

Meral & Yüksel [62]. employed a magnetic device to correct AOB. Participants were given an MAD IV appliance to wear, and results were observed. The age of participants were 9–13 years. Furthermore, Cayley et al. [51] analysed open bite and non-open bite through the evaluation of pronunciation of phenomes on 16 male participants aged 9–10.

Discussion

The results of this review should be considered with care. The degree of testimony on long-term outcomes of patient's treatment with AOB was substantially low, and the literatures incorporated in this review were primarily illustrative. Eminent diversity implies that an array of treatment effects and long-term outcomes of open-bite therapy can be anticipated. Article appraisal summaries must therefore be deciphered with precaution. Nonetheless, this uncontrolled sample symbolises the best evidence to date and could serve as a starting point for future studies with more meticulous designs.

In terms of the research methodologies, all studies displayed various methodologies in AOB treatment/management. Meral and Yüksel [62] included radiographic assessment with the approach of utilising a magnetic device and using a small sample size. The use of the magnetic device in conjunction with the bite block has demonstrated very effective AOB treatment throughout history. However, this study had not mentioned behavioural shaping to eliminate the AOB. While Cayley et al. [51] had introduced electropalatographic and cephalometric assessment for AOB treatment, with the methodology being solely based on behavioural changes with 16 children. Both studies had not cited relapse possibilities in regarding to treatment nor had targeted younger children where the presence of oral habits such as nutritive sucking is prevalent.

The chief well-structured studies that have sound methodology were by Van Dyck et al. and Huang et al. [34,38]. Both studies have been presented as pilot studies using a small sample size. Huang et al. [34] targeted children between the age 4–12 years and presented with dental habits and utilised stomahesive wafers as non-orthodontic therapy while Van Dyck et al. [38], employed orofacial myofunctional treatment as a principal treatment option with intervention questionnaires which played an important role in coaching the tongue to its correct position. This review has several limitations; only one author was used to evaluate the literature which may result the

Table 2 Application of eligibility criteria.

	Criterion One	Criterion Two	Criterion Three	Criterion Four
Bertoldiet al., 2005	Clinical trial	Age group randomised	Myofunctional therapy and early intervention counselling	Not applicable
Cayley et al., 2000	Clinical study	Age group between 9.35 and 10.84 years	Application of electropalatographic system.	Not applicable
Huang et al., 2015	Preliminary clinical study	Age group 4–12 years	Not applicable	Using stomahesive wafer as Non-orthodontic therapy
Maciel and Leite, 2005	Clinical exploratory study	Not specify	Intervention counselling	Not applicable
Meral and Yüksel, 2003	Clinical trial	9–13 years	Not applicable	Magnetic device as non-orthodontic therapy
Saito, 2001	Retrospective clinical evaluation	Not specify	Intervention counselling	Habit breaker devices
Van et al., 2015	A pilot randomised clinical study	7.1–10.6 years	Orofacial myofunctional treatment	Not applicable
Zimmer et al., 2011	Clinical evaluation	10–26 months	Not applicable	Novel pacifier

Table 3 The result.

Authors/year	Title	Methodology	Sample size	conclusion
Cayley et al., 2000	Electropalatographic and cephalometric assessment of tongue function in open bite and non-open bite subjects	This study utilised speech, swallowing, sounds to examine the dentofacial patterns and tongue function in open bite and non-open bite children.	Experimental group: eight 9 ± 1.02 years boys. Control group: Eight 10 ± 0.53 years boys	This study concludes that there is a need for further analysis of the differences in the pronunciation and phenomes to analyse those with open bite and non-open bite
Huang et al., 2015	Influence of non-orthodontic intervention on digit sucking and consequent anterior open bite: a preliminary study	Children records provided data on reported digit sucking habits in north-eastern Australia clinics. Non-orthodontic intervention (NOI) implemented to correct anterior open bite. NOI included orofacial myofunctional therapy and stomahesive wafers to guide the tongue tip to rest close to the incisive papilla.	Experimental group: 77 age 4–14 years old. Control group: 14 age 4–12 years old.	This study demonstrated satisfactory results of NOI on the cessation of digit sucking habits and corrected the AOB. Further investigation on relapse of habitual sucking is indicated.
Meral & Yüksel., 2003	Skeletal and dental effects during observation and treatment with a magnetic device	This study involved analysis of lateral cephalograms and hand-wrist radiographs of patients with AOB. Participants were observed prior to orthodontic intervention and then provided with an MAD IV appliance to wear.	16 patients (eight boys and eight girls) with age group 9.5–13.5 years old	This study suggests further assessment is indicated to analyse the changes in retention and post retention for period to assess stability in AOB patients showing aberrant growth
Van Dyck et al., 2016	The effect of orofacial myofunctional treatment in children with anterior open bite and tongue dysfunction: a pilot study.	This study was based on assigning participants into OMT and non-OMT groups. Functional characteristics such as tongue posture at rest, swallowing patterns and articulation as well as presence of AOB were observed.	22 children (11 boys, 11 girls; age range: 7.1–10.6 years)	This study concludes that OMT is effective in influencing positive tongue behaviour. Further investigation is recommended to assess long term effects for a larger population

review to be subjected to bias, non-English articles were excluded and the only search engine utilised was PubMed.

Conclusion

In conclusion, within the limitations of the study, this review recommends that oral myofunctional therapy and non-orthodontic intervention be used in conjunction as an effective treatment option for Anterior Open Bite. Further investigation on more standardised treatment options using NOI and OMT in the management of AOB is necessary.

References

- [1] Türp J, Greene C, Strub J. Dental occlusion: a critical reflection on past, present and future concepts. *J Oral Rehabil* 2008;35:446–53.
- [2] Beane RA. Nonsurgical management of the anterior open bite: a review of the options. *Semin Orthod* 1999;5:275–83.
- [3] Chang YI, Moon SC. Cephalometric evaluation of the anterior open bite treatment. *Am J Orthod Dentofacial Orthop* 1999; 115:29–38.
- [4] Shapiro PA. Stability of open bite treatment. *Am J Orthod Dentofacial Orthop* 2002;121:566–8.

- [5] Subtelny J, Musgrave K. Open bite treatment: the why of success or failure. In: Cook JT, editor. Transactions of the third international orthodontic congress, London, 1973. St Louis, MO: Mosby; 1975. p. 432–45.
- [6] Cangialosi TJ. Skeletal morphologic features of anterior open bite. *Am J Orthod* 1984;85:28–36.
- [7] Haralabakis N, Yiagtzis S, Toutountzakis N. Cephalometric characteristics of open bite in adults: a three-dimensional cephalometric evaluation. *Int J Adult Orthod Orthognath Surg* 1993;9:223–31.
- [8] Lopez-Gavito G, Wallen TR, Little RM, Joondeph DR. Anterior open-bite malocclusion: a longitudinal 10-year postretention evaluation of orthodontically treated patients. *Am J Orthod* 1985;87:175–86.
- [9] Nahoum HI. Vertical proportions: a guide for prognosis and treatment in anterior open-bite. *Am J Orthod* 1977;72:128–46.
- [10] Nielsen IL. Vertical malocclusions: etiology, development, diagnosis and some aspects of treatment. *Angle Orthod* 1991;61:247–60.
- [11] Subtelny JD, Sakuda M. Open-bite: diagnosis and treatment. *Am J Orthod* 1964;50:337–58.
- [12] Frost DE, Fonseca RJ, Turvey TA, Hall DJ. Cephalometric diagnosis and surgical-orthodontic correction of apertognathia. *Am J Orthod* 1980;78:657–69.
- [13] Lawry DM, Heggie AA, Crawford EC, Ruljancich M. A review of the management of anterior open bite malocclusion. *Aust Orthod J* 1990;11:147.
- [14] Mohlin B, Kuroi J. To what extent do deviations from an ideal occlusion constitute a health risk? *Swed Dent J* 2002;27:1–10.
- [15] Cozza P, Mucedero M, Baccetti T, Franchi L. Early orthodontic treatment of skeletal open-bite malocclusion: a systematic review. *Angle Orthod* 2005;75:707–13.
- [16] Parker JH. The interception of the open bite in the early growth period. *Angle Orthod* 1971;41:24–44.
- [17] Zuroff JP, Chen S-H, Shapiro PA, Little RM, Joondeph DR, Huang GJ. Orthodontic treatment of anterior open-bite malocclusion: stability 10 years postretention. *Am J Orthod Dentofacial Orthop* 2010;137:302 e301–302 e308.
- [18] Björk A. Prediction of mandibular growth rotation. *Am J Orthod* 1969;55:585–99.
- [19] Sassouni V. A classification of skeletal facial types. *Am J Orthod* 1969;55:109–23.
- [20] Ellis E, McNamara JA. Components of adult Class III open-bite malocclusion. *Am J Orthod* 1984;86:277–90.
- [21] Kawakami M, Yamamoto K, Noshi T, Miyawaki S, Kirita T. Effect of surgical reduction of the tongue on dentofacial structure following mandibular setback. *J Oral Maxillofac Surg* 2004;62:1188–92.
- [22] Miyawaki S, Oya S, Noguchi H, Takano-Yamamoto T. Long-term changes in dentoskeletal pattern in a case with Beckwith-Wiedemann syndrome following tongue reduction and orthodontic treatment. *Angle Orthod* 2000;70:326–31.
- [23] Fujiki T, Inoue M, Miyawaki S, Nagasaki T, Tanimoto K, Takano-Yamamoto T. Relationship between maxillofacial morphology and deglutitive tongue movement in patients with anterior open bite. *Am J Orthod Dentofacial Orthop* 2004;125:160–7.
- [24] Watson WG. Open-bite—a multifactorial event. *Am J Orthod* 1981;80:443–6.
- [25] Vaden JL, Pearson LE. Diagnosis of the vertical dimension. *Semin Orthod* 2002;8:120–9.
- [26] Wolford LM. Idiopathic condylar resorption of the temporomandibular joint in teenage girls (cheerleaders syndrome). *Proc (Bayl Univ Med Cent)* 2001;14:246–52.
- [27] Popovich F, Thompson GW. Thumb-and finger-sucking: its relation to malocclusion. *Am J Orthod* 1973;63:148–55.
- [28] Straub WJ. Malfunction of the tongue: Part I. The abnormal swallowing habit: its cause, effects, and results in relation to orthodontic treatment and speech therapy. *Am J Orthod* 1960;46:404–24.
- [29] Straub WJ. Malfunction of the tongue: Part II. The abnormal swallowing habit: its causes, effects, and results in relation to orthodontic treatment and speech therapy. *Am J Orthod* 1961;47:596–617.
- [30] Straub WJ. Malfunction of the tongue Part III. *Am J Orthod* 1962;48:486–503.
- [31] Lin L-H, Huang G-W, Chen C-S. Etiology and treatment modalities of anterior open bite malocclusion. *J Exp Clin Med* 2013;5:1–4.
- [32] Barbre RE, Sinclair PM. A cephalometric evaluation of anterior open bite correction with the magnetic active vertical corrector. *Angle Orthod* 1991;61:93–102.
- [33] Benkert K. The effectiveness of orofacial myofunctional therapy in improving dental occlusion. *Int J Orofac Myofunct Off Pub Int Assoc Orofac Myofunct* 1996;23:35–46.
- [34] Huang B, Lejarraga C, Franco CS, Kang Y, Lee A, Abbott J, et al. Influence of non-orthodontic intervention on digit sucking and consequent anterior open bite: a preliminary study. *Int Dent J* 2015;65:235–41.
- [35] Huang GJ, Justus R, Kennedy DB, Kokich VG. Stability of anterior open bite treated with crib therapy. *Angle Orthod* 1990;60:17–24.
- [36] Ngan P, Fields H. Open bite: a review of etiology and management. *Pediatr Dent* 1996;19:91–8.
- [37] Smithpeter J, Covell D. Relapse of anterior open bites treated with orthodontic appliances with and without orofacial myofunctional therapy. *Am J Orthod Dentofacial Orthop* 2010;137:605–14.
- [38] Van Dyck C, Dekeyser A, Vantricht E, Manders E, Goeleven A, Fieuws S, et al. The effect of orofacial myofunctional treatment in children with anterior open bite and tongue dysfunction: a pilot study. *Eur J Orthod* 2016;38:227–34.
- [39] Bondemark L, Holm A-K, Hansen K, Axelsson S, Mohlin B, Brattstrom V, et al. Long-term stability of orthodontic treatment and patient satisfaction: a systematic review. *Angle Orthod* 2007;77:181–91.
- [40] Cooke M. Anterior open bite. Orthodontic aspects—part 1. *Dent Update* 1980;7:475.
- [41] Epker BN, Fish LC. Surgical-orthodontic correction of open-bite deformity. *Am J Orthod* 1977;71:278–99.
- [42] Haralabakis N, Papadakis G. Relapse after orthodontics and orthognathic surgery. *World J Orthod* 2005;6.
- [43] Ng CST, Wong WKR, Hagg U. Orthodontic treatment of anterior open bite. *Int J Paediatr Dent* 2008;18:78–83.
- [44] Swinnen K, Politis C, Willems G, De Bruyne I, Fieuws S, Heidbuchel K, et al. Skeletal and dento-alveolar stability after surgical-orthodontic treatment of anterior open bite: a retrospective study. *Eur J Orthod* 2001;23:547–57.
- [45] Greenlee GM, Huang GJ, Chen SS-H, Chen J, Koepsell T, Hujoel P. Stability of treatment for anterior open-bite malocclusion: a meta-analysis. *Am J Orthod Dentofacial Orthop* 2011;139:154–69.
- [46] Haymond CS, Stoelinga PJ, Blijdorp PA, Leenen RJ, Merckens NM. Surgical orthodontic treatment of anterior skeletal open bite using small plate internal fixation: one to five year follow-up. *Int J Oral Maxillofac Surg* 1991;20:223–7.
- [47] Denison TF, Kokich VG, Shapiro PA. Stability of maxillary surgery in open bite versus nonopenbite malocclusions. *Angle Orthod* 1989;59:5–10.
- [48] Franco FCM, Araújo TMD, Habib F. Pontas ativas: um recurso para o tratamento da mordida anterior. *Ortodon Gaúch* 2001;5:6–12.
- [49] Miller H. The early treatment of anterior open bite. *Int J Orthod* 1969;7:5.
- [50] Yashiro K, Takada K. Tongue muscle activity after orthodontic treatment of anterior open bite: a case report. *Am J Orthod Dentofacial Orthop* 1999;115:660–6.

- [51] Cayley A, Tindall A, Sampson W, Butcher A. Electropalato-graphic and cephalometric assessment of myofunctional therapy in open-bite subjects. *Aust Orthod J* 2000;16:23–33.
- [52] Takahashi O, Iwasawa T, Takahashi M. Integrating orthodontics and oral myofunctional therapy for patients with oral myofunctional disorders. *Int J Orofac Myol Off Pub Int Assoc Orofac Myol* 1995;21:66–72.
- [53] Haryett R, Hansen F, Davidson P, Sandilands ML. Chronic thumb-sucking: the psychologic effects and the relative effectiveness of various methods of treatment. *Am J Orthod* 1967;53:569–85.
- [54] Justus R. Correction of anterior open bite with spurs: long-term stability. *World J Orthod* 2001;2:219–31.
- [55] Meyer-Marcotty P, Hartmann J, Stellzig-Eisenhauer A. Den-toalveolar open bite treatment with spur appliances. *J Orofac Orthop* 2007;68:510–21.
- [56] Cozza P, Baccetti T, Franchi L, McNamara JA. Treatment effects of a modified quad-helix in patients with dentoskeletal open bites. *Am J Orthod Dentofacial Orthop* 2006;129:734–9.
- [57] Haryett R, Hansen F, Davidson P. Chronic thumb-sucking: a second report on treatment and its psychological effects. *Am J Orthod* 1970;57:164–78.
- [58] Villa NL, Cisneros GJ. Changes in the dentition secondary to palatal crib therapy in digit-suckers: a preliminary study. *Pediatr Dent* 1996;19:323–6.
- [59] Rogers AP. Open-bite cases involving tongue habits. *Int J Orthod Oral Surg Radiogr* 1927;13:837–44.
- [60] Bisase B, Johnson P, Stacey M. Closure of the anterior open bite using mandibular sagittal split osteotomy. *Br J Oral Maxillofac Surg* 2010;48:352–5.
- [61] Gracco A, Siviero L, de Stefani A, Bruno G, Stellini E. Anterior open-bite orthodontic treatment in an adult patient: a clinical case report. *Int Orthod* 2016;14:171–83.
- [62] Meral O, Yüksel S. Skeletal and dental effects during obser-vation and treatment with a magnetic device. *Angle Orthod* 2003;73:716–22.
- [63] Mucedero M, Franchi L, Giuntini V, Vangelisti A, McNamara Jr JA, Cozza P. Stability of quad-helix/crib therapy in dentoskeletal open bite: a long-term controlled study. *Am J Orthod Dentofacial Orthop* 2013;143:695–703.
- [64] Burford D, Noar J. The causes, diagnosis and treatment of anterior open bite. *Dent Update* 2003;30:235–41.