



# Chasing Pain

Diagnosing and Treating  
Trigeminal Neuralgia  
in General Dentistry

by Steven Olmos, DDS, DABCP, DABCDMS, DABDSM, DAAPM, FAAOP, FAACP, FICCMO, FADI, FIAO

As dentists, we know quite a bit about tooth and gum pain, but when it comes to chronic facial pain and neuropathic pain, our dental school education leaves us unprepared. The objective of this article is to explain the differences between men and women with chronic orofacial pain and the relationship to proper functional breathing, using a case study as demonstration.

In the United States, nearly half of all adults lived with chronic pain in 2011. Of 353,000 adults aged 18 years or older who were surveyed by Gallup-Healthways, 47 percent reported having at least one of three types of chronic pain: neck or back pain, knee or leg pain, or recurring pain.<sup>2</sup>

A study published in *The Journal of the American Dental Association* October 2015 stated: "One in six patients visiting a general dentist had experienced orofacial pain during the last year. Pain in the muscles and temporomandibular joints was reported as frequently as that in the teeth and surrounding tissues in patients visiting general dentists."

The practical implications for this study were as follows: "Although the dental curriculum is concentrated on the diagnosis and management of pain and related conditions from teeth and surrounding tissues, it is imperative to include the training for other types of orofacial pain, particularly those from temporomandibular joint and musculoligamentous tissues."<sup>3</sup>

Pain in the orofacial regions affects 21.7 percent of the population in the United States and costs more than \$32 billion each year.<sup>4</sup>

Patients over the age of 45 and women have the highest prevalence of facial pain. Women have higher incidence for musculoskeletal pain.<sup>5</sup> Hormones play a role in chronic pain/TMD, as testosterone reduces pain transmission<sup>6</sup> and estrogen exacerbates pain in the face and jaw.<sup>7</sup>

An established relationship exists between OSA and TMD.<sup>8,9</sup> Two studies tested the hypothesis that OSA signs and symptoms were associated with TMD: the OPPERA prospective cohort study of adults aged 18–44 years at enrollment (n = 2,604) and the OPPERA case-control study of chronic TMD (n = 1,716). Both studies supported a significant association between OSA symptoms and TMD, with prospective cohort evidence finding that OSA symptoms preceded first-onset of TMD: patients with two or more signs and/or symptoms of OSA had a 73 percent greater incidence of first-onset TMD.

So breathing and facial pain/TMD are linked by sleep bruxism (SB), as the method of chronic irritation to the joint structures and facial muscles. SB has been linked to maintaining airway patency in OSA,<sup>10</sup> however the most recent

research published in *Chest 2015* demonstrates that respiratory-effort-related arousal may be the most likely cause (nasal obstruction or mouth breathing).<sup>11</sup> Rising CO<sub>2</sub> (hypercapnia) in a patient with a sleep-breathing disorder (including mouth breathing) specifically stimulates the superficial masseter muscles to contract.<sup>12</sup>

Identifying the structural area of obstruction (Four Points of Obstruction; Fig. 1) of the airway will insure the most effective treatment for a sleep-breathing disorder and effectively reduce the facial muscle contraction, which in turn will result in reduction of facial-pain complaints and nerve entrapments (trigeminal neuralgia). It will also insure proper swallowing and tongue posture that will result in reduced orthodontic relapse (anterior and lateral open bite).<sup>13</sup>

### Trigeminal neuralgia

Classical trigeminal neuralgia (TN) is a disease of severe, stabbing neuropathic facial pain of the second and third divisions of the trigeminal nerve.<sup>14</sup> It is estimated that one in 15,000 people suffers from trigeminal neuralgia; however, numbers may be significantly higher due to frequent misdiagnosis.<sup>15</sup> The incidence is greatest in people more than 50 years of age, and in women more frequently than men.<sup>16</sup>

It has also been reported that 26 percent of the American population is at high risk of obstructive sleep apnea (OSA), a sleep breathing disorder (SBD), indicating as many as one in four Americans could benefit from an evaluation for OSA.<sup>17</sup> In the same report, 57 percent of obese individuals were at high risk for OSA. Obesity is defined as a BMI (body mass index) of 30 or greater.

This case study seeks to demonstrate a long-term cure for trigeminal neuralgia utilizing low-level laser therapy and treatment for nasal obstruction.

This case demonstrates relief of chronic facial pain of the mandibular division of the trigeminal nerve as it innervates the muscles of mastication (Fig. 2; see p. 36).

Trigeminal neuropathy can have many origins, such as a neoplastic growth compressing the nerve as it leaves the pons and before it leaves the cranium through either the foramen rotundum (maxillary division, blue arrow) or foramen ovale (mandibular division, green arrow) (Fig. 3; see p. 36). Tumors, usually posterior fossa meningioma



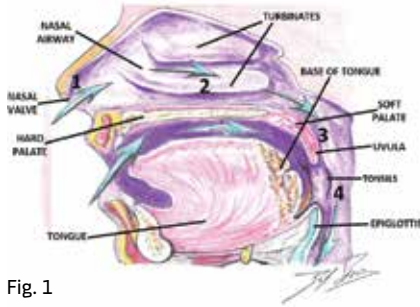


Fig. 1

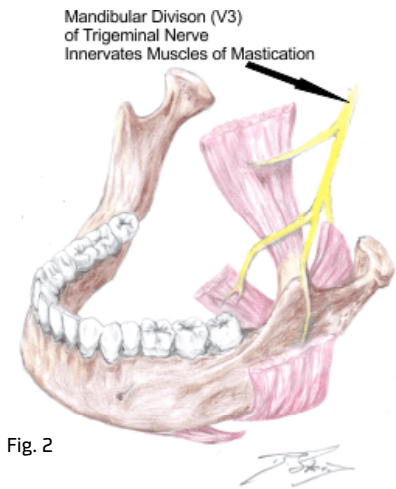


Fig. 2

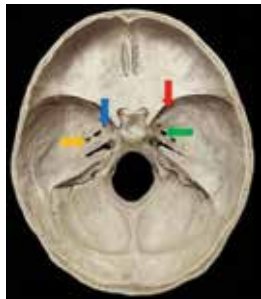

Fig. 3

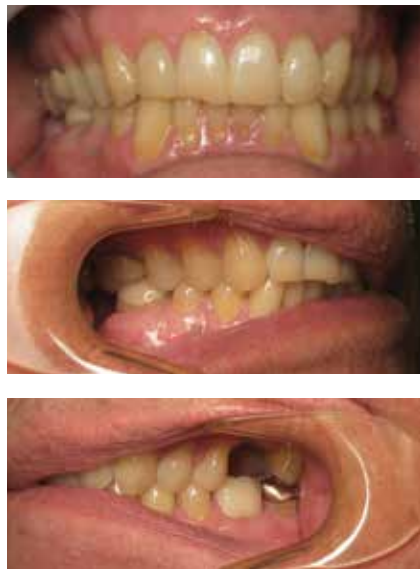

Fig. 4

or neuromas, are found in 2 percent of patients who present with typical TGN.<sup>18</sup> Surgical excision is indicated for these conditions as diagnosed via MRI.

Another source of trigeminal neuralgia can be enlargement of the middle meningeal artery that can compress the mandibular division as it leaves the skull through the foramen ovale.

The middle meningeal artery is a branch of the maxillary artery in the infratemporal fossa. It enters the skull through the foramen spinosum (yellow arrow, Fig. 3), and is within the dura mater lining the cranial cavity. The critical abnormality is vascular contact at the dorsal root entry zone, rather than more distally; such is seen in 3 percent to 12 percent of trigeminal nerves at autopsy.<sup>19, 20</sup> Brain surgery (microvascular decompression) is necessary to treat this condition.

The most common source of trigeminal neuralgia is peripheral entrapment of the nerve by the muscles it innervates, or mechanical trauma (injury). There is damage to the myelin sheath that lowers the capacitance of the nerve that lowers its threshold for conduction. There is a spontaneous transmission of pain in a sensory nerve by contractions of the muscles it innervates or a structure that it passes through. It has been my experience that mandibular trigeminal neuralgia is often present in combination with a movement disorder termed bruxism. Bruxism is an exacerbation of normal rhythmic masticatory muscle activity that results in wear of dentition and muscle-pain disorders. The brain is stimulated by a variety of factors, including pain, medications and sleep-related breathing disorders.<sup>21</sup>

Treatment for trigeminal neuralgia is usually medicinal. Membrane-stabilizing drugs, anticonvulsants, centrally acting muscle relaxants—individually or in combination—are used. Doses are increased over time as tolerance and metabolism of the drugs increase and their effectiveness decreases.

When maximum dosage for each

individual drug has been reached it is lowered and an additional drug is combined until maximum dosage is reached and a third drug or new combination is tried. Commonly used drugs are Tegretol (carbamazepine), Neurontin (gabapentin), Lamictal (lamotrigine), Klonopin (clonazepam), Baclofen, and Lyrica (pregabalin).

The clinical efficacy of low-level laser therapy (LLT) in the treatment of neuropathic pain is well established in many studies.<sup>22, 23, 24, 25, 26, 27, 28, 29, 30, 31, 32</sup> This is a very important tool for the treatment of nerve injuries, as all other treatments are palliative, while the laser therapy is truly therapeutic.

### Case study

Craig, a 66-year-old man, was referred to our office by an oral maxillo-facial surgeon for the relief of left mandibular episodic facial pain neuralgia. His chief complaints were chronic pain (four years) when chewing, jaw and facial pain. He had spontaneous shooting pain on the left side of his face. He said he could relate it to a Novocain injection and a tooth implant. He was currently being treated with carbamazepine 100mg four times daily, but the pain was not controlled. He had previously been treated with gabapentin 300mg three times per day until it became ineffective. He sometimes took alcohol and sedatives for pain relief or sleeping.

Positive findings from his health history were high blood pressure, stroke, asthma, hepatitis, and frequent wakening at night.

Our clinical findings at the time of examination were: BMI 31.07, B.P. 166/100, pulse 64, respiration 16, temperature 98.2°. Orthopedic mandibular ranges of motion were 56mm without pain, left and right lateral movements of 10mm, and 9mm of protrusion. Dental examination demonstrated molar Class I occlusion, with 4mm of overjet and overbite, with worn dentition (bruxism, see Fig. 4).

*Continued on p. 38*

Continued from p. 36

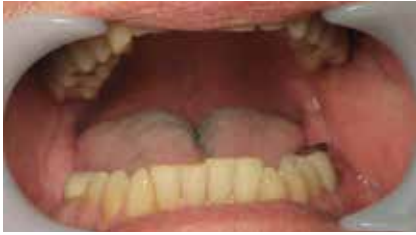

Fig. 5

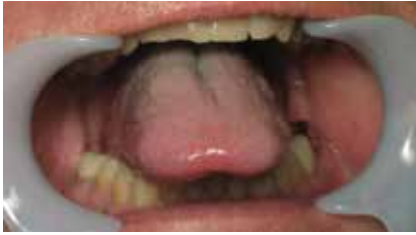
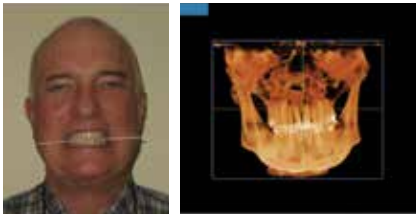
Fig. 6



Figs. 7 & 8

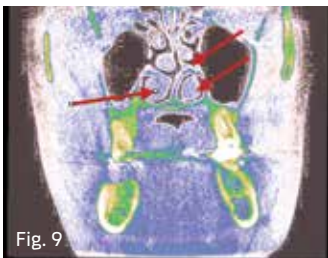


Fig. 9

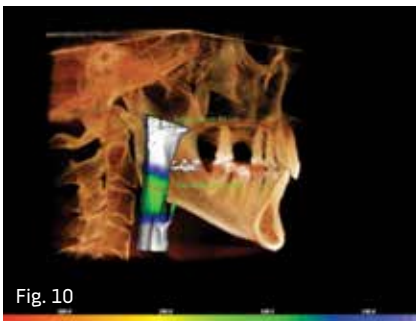


Fig. 10

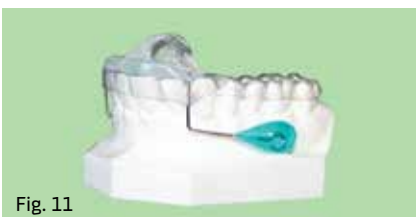

Fig. 11

Oral evaluation demonstrated Malampati Class IV, furrowed tongue, coating of the tongue (indicating mouth breathing from nasal obstruction), and scalloping of the tongue, which are both indicative of a sleep-related breathing disorder (Figs. 5 & 6).

There were no positive findings for muscle, tendon and ligament palpation. Imaging utilizing CBCT (cone-beam computed tomography) demonstrated a significant cant of the mandible to the left side (affected side) and was confirmed with a photograph of the patient with a tongue blade (Figs. 7 & 8). This indicates that the elevator muscles or muscles of mastication are shorter on the left than the right. When muscles are shorter than their resting length, they have greater resting tonus or tension.

Nasal obstruction was observed from the iCAT CBCT, with deviation of the septum to the left with nasal soft-tissue hypertrophy (Fig. 9). The oropharyngeal airway appears to be within normal dimensions while the patient is awake, however it does not measure how much it can collapse while asleep (Fig. 10).

The diagnosis for this patient was trigeminal neuralgia with suspected sleep-related breathing disorder, nasal obstruction, nasal-valve compromise, and bruxism. The treatment plan consisted of:

1. Decompression appliance therapy, a night orthotic that prevents mandibular retrusion, reduces clenching forces and opens nasal valve (Fig. 11), for cant correction and leveling of the occlusal plane utilizing the phonetic or sibilant phoneme registration<sup>33</sup> and reducing of oropharyngeal airway collapse while sleeping; with combined use of weekly treatments with the ASA Mphi laser at 50 percent intensity, frequency of 100 Hz, for two to three minutes, utilizing energy of 30 joules; and carbamazepine 100mg, four times per day. Treatment time 10 to 12 weeks and re-evaluation.

2. Referral to sleep physician for diagnostic PSG (polysomnography).

3. Referral to ENT physician for

evaluation and treatment of nasal obstructions.

### Treatment results

At four weeks of the combined treatment of decompression, carbamazepine and weekly applications with the Mphi laser, the facial pain and jaw pain had resolved, and the pain when chewing had reduced between 40 percent to 50 percent.

The unique synergistic use of two wavelengths of energy (808 and 905), using both pulsed and continuous (chopped) application is superior to either pulsed or continuous laser systems. The laser was used from the peripheral point of the innervation of the masseter nerve working back centrally toward its origin.

The laser stimulates regeneration of tissue by increasing the function of the mitochondria, therefore changing the DNA and biometric form of the cells.<sup>34, 35</sup> This is stimulating and therefore the patient needs to be on the membrane-stabilizing medication during the healing process to prevent excitation by the laser. Once the nerve healing is complete and it retains its normal threshold or capacitance, the need for medications is unnecessary.

At eight weeks of combined therapy and weekly applications of the Mphi laser, the pain when chewing was resolved as well as the facial and jaw pain. At this point I recommended reduction of the carbamazepine dosage by one third and continued reduction until elimination of the drug or return of pain symptoms. The patient finally agreed to have a sleep study (PSG), and I wrote the prescription for referral.

At 11 weeks he had attended a sleep study (PSG) and the results were overall moderate apnea with an AHI of 26.0 and a REM AHI of 40.4 (severe). He had zero (0) stage 3 delta wave restorative sleep and his lowest oxygen desaturation was 82 percent. His periodic limb movement (PLM) index was 21.4. He was diagnosed with obstructive sleep apnea and PLM disorder.

Continued on p. 40



It has also been reported that 26 percent of the American population is at high risk of obstructive sleep apnea (OSA), a sleep breathing disorder (SBD), indicating as many as one in four Americans could benefit from an evaluation for OSA.<sup>1</sup>

Upon re-evaluation at 13 weeks of treatment, the patient had completely weaned off all medications and was symptom-free. He chose not to treat his OSA, and his PSG testing was performed without the decompression appliance. He found that he had a slight tingling of the same injured nerve when he did not wear his oral decompression appliance for three nights. It was explained to the patient the severe health risks of untreated OSA.

This article demonstrates the relationship between trigeminal nerve injury and muscle contraction disorders such as those found in patients with sleep-related breathing disorders. Most importantly, it demonstrates the value of low-level laser therapy, utilizing the unique delivery of the Mphi laser system on healing injured nerves. This is the most remarkable tool that I have seen in my 30 years of treating chronic-pain disorders. ■

References

- Hiestand DM, Britz P, Goldman M, Phillips B (2006) Prevalence of symptoms and risk of sleep apnea in the US population: Results from the national sleep foundation sleep in America 2005 poll. *Chest* 130 (3):780-786. doi:10.1378/chest.130.3.780
- Brown A. Chronic pain rates shoot up until Americans reach late 50s. Available at <http://www.gallup.com/poll/154169/Chronic-Pain-Rates-Shoot-Until-Americans-Reach-Late-50s.aspx>
- Horst O.V., D. Cunha-Cruz J.; Zhou L.; Manning W. et. al. Prevalence of pain in the orofacial regions in patients visiting general dentists in the Northwest Practice-based Research Collaborative in Evidence-based Dentistry research network. *JADA* 146(10) <http://jada.ada.org> October 2015
- Centers for Disease Control and Prevention. National Center for Health Statistics. National Health and Nutrition Examination Survey Data. 2002. Available at: <http://www.cdc.gov/nchs/nhanes.htm>. Accessed May 18, 2015.
- Cairns BE, Hu JW, Arendt-Nielsen L, Sessle BJ, Svensson P. Sex-related differences in human pain and rat afferent discharge evoked by injection of glutamate into the masseter muscle. *J Neurophysiology* 2001;86:782-791.
- Fischer L, Clemente JT, Tambelli CH. The Protective Role of Testosterone in the Development of Temporomandibular Joint Pain. *J Pain* 2007 Mar 12.
- Flake NM, Bonebreak DB, Gold MS. Estrogen and inflammation increase the excitability of rat temporomandibular afferent neurons. *J Neurophysiology* 2005 Mar;93(3):1585-97.
- Smith MT, Wickwire EM, Grace EG, et al. Sleep disorders and their association with laboratory pain sensitivity in temporomandibular joint disorder. *Sleep* 2009; 32: 779-90.
- Sanders AE, Essick GK, Fillingim R, et al. Sleep apnea symptoms and risk of temporomandibular disorder: OPERA cohort. *J Dent Res* 2013; 92: 70S-7S.
- Simmons JH, Prehn RS. Nocturnal bruxism as a protective mechanism against obstructive breathing during sleep. *Sleep* 2008; 31: A199.
- Mayer P, Heinzer R, Lavigne G. *Sleep Bruxism in Respiratory Medicine Practice*. Chest 2015.
- Hollowell DE, Bhandary PR, Funsten AW, Surat PM. Respiratory-related recruitment of the masseter: response to hypercapnia and loading. *J Appl Physiol* (1985) 1991; 70: 2508-13.
- Olmos S. CBCT in the evaluation of airway- minimizing orthodontic relapse. *Journal of Orthodontic Practice*, March/April 2015, pg. 35-37.
- Katusic S, Beard CM, Bergstralh E, Kurland LT. Incidence and clinical features of trigeminal neuralgia, Rochester, Minnesota, 1945-1984. *Ann Neurol*. 1991;27:89-95.
- Cheshire WPJ, Wharen REJ. Trigeminal neuralgia in a patient with spontaneous intracranial hypotension. *Headache*. 2009;49:770-3.
- National Institute of Neurological Disorders and Stroke, National Institutes of Health, Bethesda, MD
- Hiestand DM, Britz P, Goldman M, Phillips B (2006) Prevalence of symptoms and risk of sleep apnea in the US population: Results from the national sleep foundation sleep in America 2005 poll. *Chest* 130 (3):780-786. doi:10.1378/chest.130.3.780
- Cheng TMW, Cascino TL, Onofrio BM. Comprehensive study of diagnosis and treatment of trigeminal neuralgia secondary to tumors. *Neurology* 1993; 43: 2298-302
- Hamlyn PJ, King TJ. Neurovascular compression in trigeminal neuralgia: a clinical and anatomical study. *J Neurosurg* 1992; 76: 948-52
- Hardy DG, Rhoton AL Jr. Microsurgical relationships of the superior cerebellar artery and trigeminal nerve. *J Neurosurg* 1978; 49: 669-78
- Pierre Mayer, Raphael Heinzer and Gilles Lavigne. *Sleep Bruxism in Respiratory Medicine Practice*. Chest 2015, online published, <http://journal.publications.chestnet.org/>
- Iijima K, Shimoyama N, Shimoyama M, Yamamoto T, Shimizu T, Mizuguchi T. Effect of repeated irradiation of low-power He-Ne laser in pain relief from postherpetic neuralgia. *Clin J Pain*. 1989;5:271-4.
- Walker J, Akhanjee L, Cooney M, Goldstein J, Tamayoshi S, Segal-Gidan F. Laser therapy for pain of trigeminal neuralgia. *Clin J Pain*. 1988;3:183-7.
- Iijima K, Shimoyama N, Shimoyama M, Mizuguchi T. Evaluation of analgesic effect of low-power He:Ne laser on postherpetic neuralgia using VAS and modified McGill pain questionnaire. *J Clin Laser Med Surg*. 1991;9:121-6.
- Walker J. Relief from chronic pain by low power laser irradiation. *Neurosci Lett*. 1983;43:339-44.
- Eckerdal A, Bastian H. Can low reactive-level laser therapy be used in the treatment of neurogenic facial pain? A double-blind, placebo controlled investigation of patients with trigeminal neuralgia. *Laser Therapy*. 1996;8:247-52.
- Moore K, C., Hira N, Kramer PS, Jayakumar CS, Ohshiro T. Double blind crossover trial of low level laser therapy. *Practical Pain Management* 1988;1-7.
- Samosiuk IZ, Kozbanova AK, Samosiuk NI. [Physiopuncture therapy of trigeminal neuralgia]. *Vopr Kurortol Fizioter Lech Fiz Kult* 2000;29-32. [In Russian].
- Vernon LF. Low-level laser for trigeminal neuralgia. *Practical Pain Management* 2008;56-63.
- Kemmotsu O, Sato K, Furumido H, Harada K, Takigawa C, Kaseno S. Et al. Efficacy of low reactive-level laser therapy for pain attenuation of postherpetic neuralgia. *Laser Therapy*. 1991;3:71-5.
- Kim HK, Jung JH, Kim CH, Kwon JY, Baik SW. The effect of lower level laser therapy on trigeminal neuralgia. *Journal of the Korean Pain Society*. 2003;16:37-41.
- Mann SS, Dewan SP, Kaur A, Kumar P, Dhawan AK. Role of laser therapy in post herpetic neuralgia. *Indian J Dermatol Venereol Leprol*. 1999;65:134-6.
- D. Singh, S. Olmos. Use of a sibilant phoneme registration protocol to prevent upper airway collapse in patients with TMD. *Sleep Breath* 2007.
- Mognato M, Squizzato F, Facchin F, Zaghetto L., Corti L. *Pho-tomedicine and Laser Surgery* (2004) Vol 22, n. 6 - 523-526
- Gigo-Benato D. Et al. *Lasers Med Sci*. 2004;19(1):57-65.

What is your experience with facial pain? Comment on this article at [Dentaltown.com/magazine.aspx](http://Dentaltown.com/magazine.aspx).

Author Bio



Dr. Steven Olmos has been in private practice for more than 30 years, with the last 20 years devoted to research and treatment of craniofacial pain, temporomandibular disorder (TMD), and sleep-disordered breathing. He obtained his DDS from the University of Southern California School of Dentistry and is Board Certified in both chronic pain and Sleep Related Breathing Disorders.

Dr. Olmos is the founder of TMJ & Sleep Therapy Centres International, with 35 licensed locations in six countries dedicated exclusively to the diagnosis and treatment of craniofacial pain and sleep disorders. Dr. Olmos is an adjunct professor at the University of Tennessee School of Dentistry.